

Research Article

ROLE OF ULTRASOUND IN SCROTAL EMERGENCIES: A PROSPECTIVE OBSERVATIONAL STUDY

Dr. D. B. Dahiphale¹, Dr. P. S. Mishrikotkar², Dr. Mangesh Pawar³

¹HOD, Department of Radiology, MGM Chh. Sambhajinagar, India.

²Professor, Department of Radiology, MGM Chh. Sambhajinagar, India.

³Resident, Department of Radiology, MGM Chh. Sambhajinagar, India.

*Corresponding Author

Dr. Mangesh Pawar, Resident,
Department of Radiology, MGM
Chh. Sambhajinagar, India.

Email:
mangeshpawar3009@gmail.com

Article History

Received: 15.01.2026

Revised: 22.02.2026

Accepted: 17.03.2026

Published: 30.03.2026

Citations:

Dahiphale, D. B., Mishrikotkar, P. S., & Pawar, M. Role of ultrasound in scrotal emergencies: A prospective observational study. *J Surg Radiol*, V5(3) 30-36.

Abstract: **Introduction:** Scrotal emergencies constitute a significant proportion of acute urological presentations and require rapid diagnosis to prevent irreversible testicular damage and preserve fertility. Clinical evaluation alone is often insufficient due to overlapping symptoms among conditions such as testicular torsion, epididymo-orchitis, trauma, and hydrocele. Ultrasonography (USG), particularly with Color Doppler, plays a crucial role in early diagnosis and management. **Aim:** To assess the diagnostic accuracy of ultrasonography in evaluating scrotal emergencies and differentiating surgical from non-surgical conditions. **Materials and Methods:** This prospective observational study was conducted in the Department of Radiology at a tertiary care center over 8 months (February–October 2025). A total of 55 patients presenting with acute scrotal pain, swelling, or trauma were included. All patients underwent high-frequency grayscale ultrasonography with Color Doppler. Findings were correlated with clinical, laboratory, and operative outcomes. Diagnostic accuracy parameters such as sensitivity and positive predictive value were analyzed. **Results:** Epididymo-orchitis was the most common diagnosis (44%), followed by testicular torsion (24%), hydrocele (18%), trauma (8%), and abscess/other pathologies (6%). Ultrasonography demonstrated high sensitivity in identifying inflammatory conditions and accurately differentiated torsion based on absent vascularity and the whirlpool sign. Early diagnosis significantly improved testicular salvage rates. **Conclusion:** Ultrasonography with Color Doppler is a rapid, non-invasive, and reliable diagnostic modality in scrotal emergencies. It effectively differentiates surgical from non-surgical conditions, reduces unnecessary surgical exploration, and improves patient outcomes.

Keywords: Scrotal emergencies, Ultrasonography, Color Doppler, Testicular torsion, Epididymo-orchitis

INTRODUCTION

Scrotal emergencies represent a critical group of urological conditions that demand immediate evaluation and timely intervention to prevent irreversible complications such as testicular infarction and infertility. Acute scrotal discomfort can be caused by anything from benign inflammatory disorders to potentially fatal surgical emergencies like testicular torsion. It is a typical presenting symptom in emergency rooms. Delays in treatment, especially in cases of torsion, can lead to irreversible testicular loss, therefore early and precise diagnosis is crucial. Testicular salvage rates can reach 90% if treatment is received within 6 hours, but they sharply decline after 24 hours, according to studies [1].

The overlapping symptoms of many scrotal diseases make clinical examination alone frequently unreliable. Pain, swelling, erythema, and soreness are common symptoms of conditions such as hydrocele, torsion, trauma, and epididymo-orchitis. Treatment delays or needless surgical investigations might result from this diagnostic ambiguity. As a result, imaging is essential for assessing scrotal crises.

Because of its accessibility, non-invasiveness, and lack of ionizing radiation, ultrasound (USG) has become the primary imaging modality for assessing acute scrotal

diseases. While Color Doppler offers crucial information on testicular perfusion, high-frequency ultrasonography enables in-depth morphological evaluation. Doppler imaging has greatly boosted diagnostic precision, especially when it comes to distinguishing between inflammatory diseases like epididymo-orchitis, which is characterized by increased vascularity, and testicular torsion, which is defined by decreased or absent blood flow [2].

Diagnosis is further aided by characteristic ultrasonographic findings. An enlarged epididymis, hypoechoic testis, and increased vascularity (hyperemia) are signs of epididymo-orchitis. Testicular torsion, on the other hand, usually manifests as an inflated hypoechoic testis with little blood flow and the extremely unique "whirlpool sign" [3]. Hematomas, fractures, or ruptures may be seen in traumatic situations, whereas hydrocele manifests as an anechoic accumulation of fluid around the testis. The use of ultrasonography in scrotal crises has been confirmed by a number of studies. The significance of Doppler ultrasonography in identifying testicular torsion and distinguishing it from inflammatory diseases was shown by Middleton et al. [4]. Its great sensitivity and specificity in assessing scrotal diseases were also noted by Dogra et al. [5].

Despite these developments, issues like operator dependence and the problem of early torsion detection still exist. As a result, ongoing assessment of ultrasonography's diagnostic capabilities is crucial. The purpose of this study is to explore the influence of ultrasonography on clinical care and results, as well as its involvement in scrotal crises and its diagnostic accuracy.

AIMS AND OBJECTIVES

1. To assess the diagnostic accuracy of ultrasonography in scrotal emergencies
2. To differentiate testicular torsion from inflammatory conditions
3. To identify characteristic ultrasonographic features of common scrotal pathologies
4. To evaluate the impact of early diagnosis on patient outcomes
5. To highlight limitations in ultrasonographic evaluation

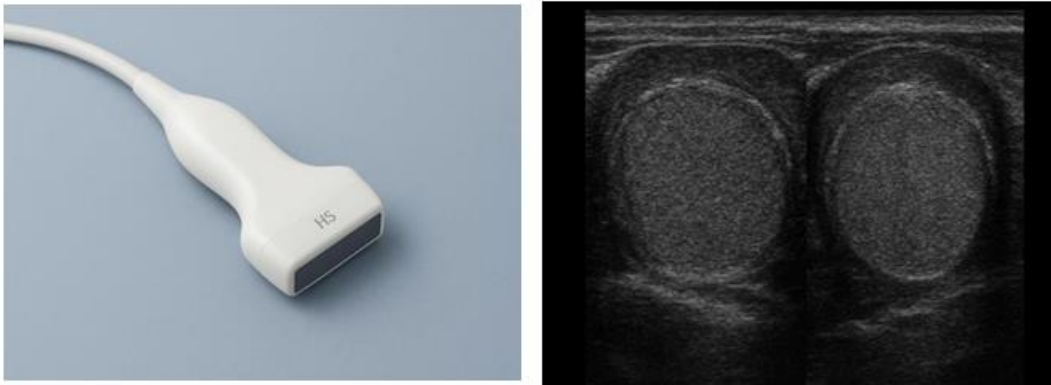


Photo 1

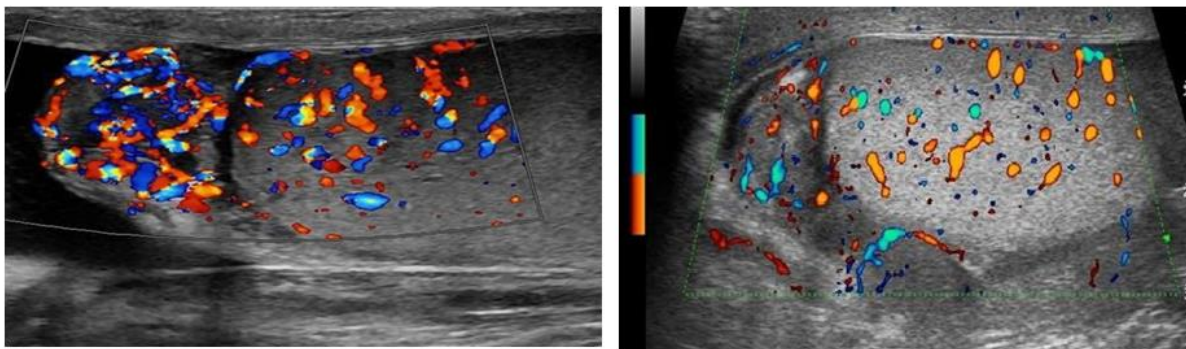


Photo 2: Epididymo-orchitis

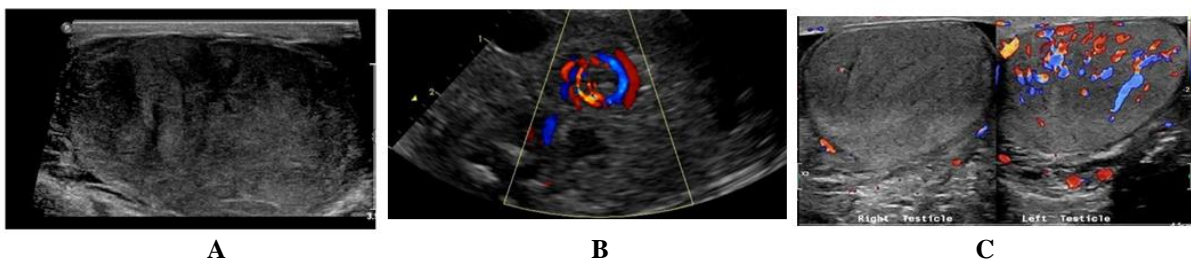


Photo 3: A. Enlarged hypoechoic testis, B-Whirlpool sign (Most specific), C- Asymmetric vascularity

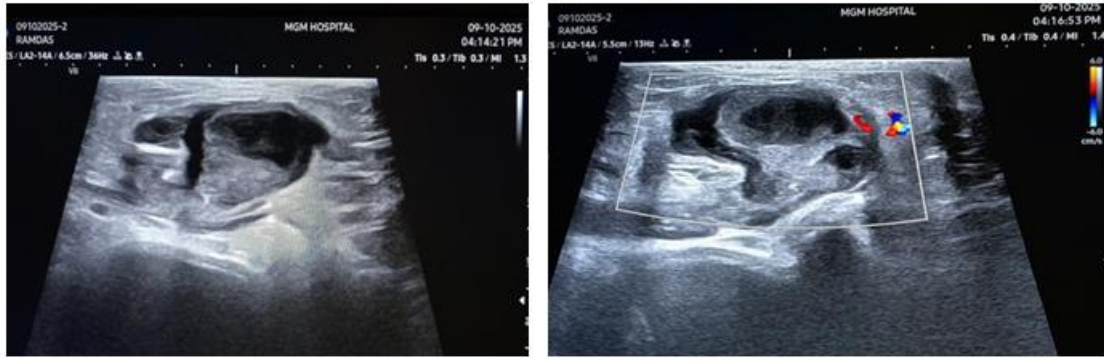
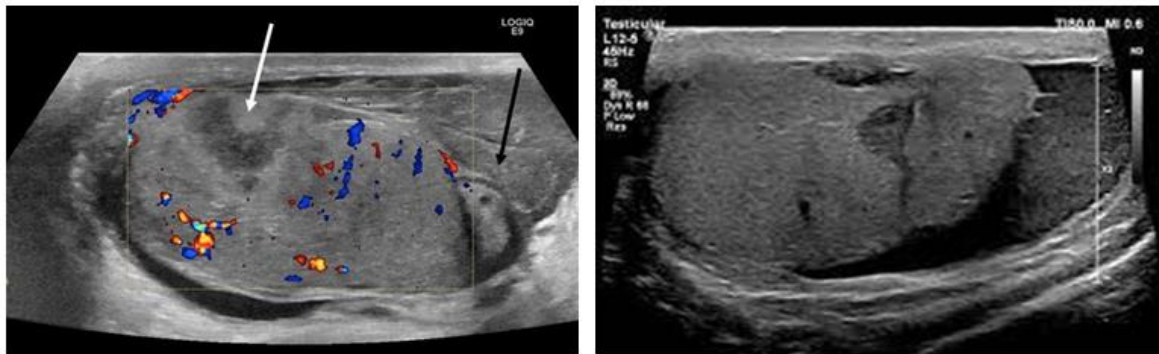


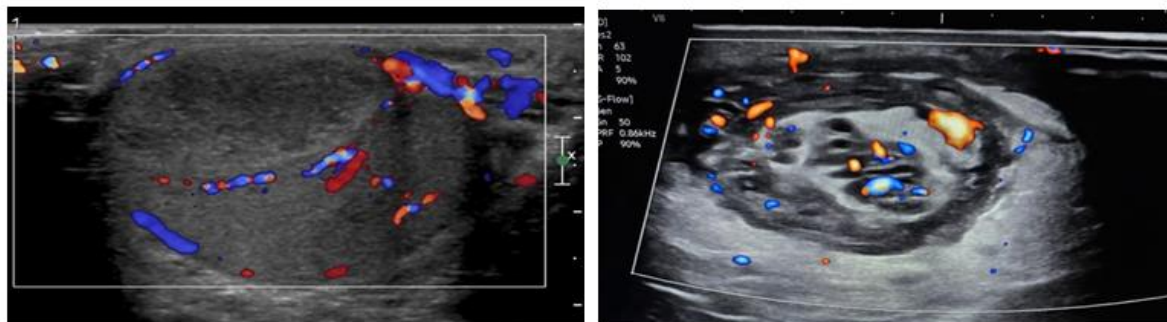
Photo 4: Torsion in Undescended testis



A. Testicular trauma

B. Testicular fracture

Photo 5



A. Testicular Abscess

B. Funiculitis

Photo 6

MATERIALS AND METHODS

Study Design: Prospective observational study.

Study Setting and Duration: Conducted in the Department of Radiology at a tertiary care center over 8 months (February–October 2025).

Sample Size: A total of 55 patients presenting with acute scrotal symptoms were included.

Inclusion Criteria

- Acute scrotal pain or swelling of less than 72 hours duration
- Clinically suspected scrotal emergencies
- Patients referred for ultrasonographic evaluation

Exclusion Criteria

- Chronic scrotal conditions
- History of prior scrotal surgery
- Incomplete clinical or imaging data

Ultrasonography Protocol

All patients underwent ultrasonographic evaluation using a high-frequency linear transducer (7–15 MHz). The protocol included grayscale imaging of the scrotal contents followed by Color and power Doppler assessment for evaluation of vascularity.

Data Collection

Clinical findings, ultrasonographic features, and operative or laboratory outcomes were recorded and analyzed for correlation.

Statistical Analysis

Diagnostic accuracy of ultrasonography was assessed using parameters such as sensitivity, specificity, and positive predictive value.

RESULTS

Table 1: Distribution of Scrotal Emergencies (n=55)

Condition	Number	Percentage
Epididymo-orchitis	24	44%
Testicular torsion	13	24%
Hydrocele	10	18%
Trauma	4	8%
Abscess & others	4	6%

The distribution of scrotal emergencies among the study population is shown in Table 1. Epididymo-orchitis was the most common diagnosis, accounting for 24 cases (44%). This was followed by testicular torsion in 13 patients (24%), making it the most frequent surgical emergency observed. Hydrocele was identified in 10 patients (18%), while scrotal trauma and abscess/other pathologies each accounted for 4 cases (8% and 6%, respectively). The findings indicate that inflammatory conditions constitute the majority of acute scrotal presentations, whereas torsion represents a significant proportion requiring urgent intervention.

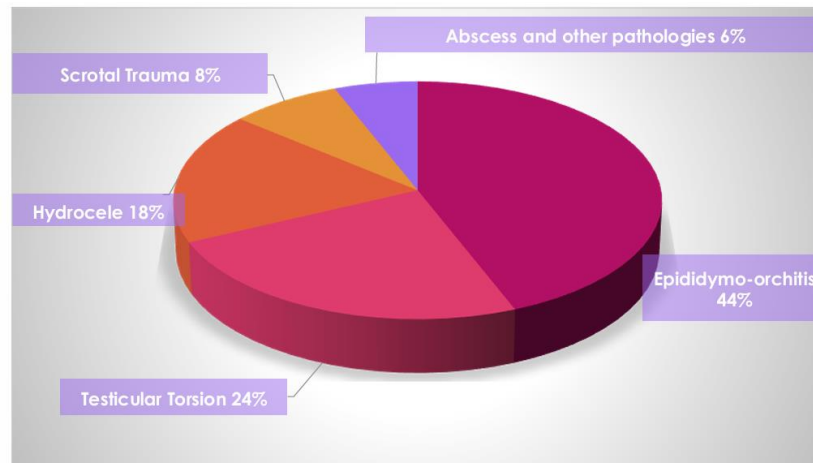


Figure 1: Distribution of Scrotal Emergencies

Table 2: Ultrasonographic Features

Condition	Key USG Findings
Epididymo-orchitis	Enlarged epididymis, hyperemia
Torsion	Hypochoic testis, absent flow
Hydrocele	Anechoic fluid
Trauma	Hematoma/fracture
Abscess	Hypochoic collection

Table 2 summarizes the characteristic ultrasonographic findings associated with different scrotal conditions. Epididymo-orchitis typically presented with an enlarged epididymis and increased vascularity (hyperemia) on Doppler imaging. Testicular torsion showed a hypochoic testis with absent or significantly reduced vascular flow. Hydrocele was characterized by anechoic fluid collection surrounding the testis. Traumatic cases demonstrated findings such as hematoma or testicular fracture, while abscesses appeared as localized hypochoic collections. These features highlight the effectiveness of ultrasonography in differentiating between various scrotal pathologies.

Table 3: Diagnostic Accuracy

Condition	Cases	True Positive	Accuracy (%)
Epididymo-orchitis	22	19	86.4
Torsion	11	10	90.9
Hydrocele	9	9	100
Trauma	7	6	85.7

Abscess	6	6	100
---------	---	---	-----

Table 3 presents the diagnostic accuracy of ultrasonography across different conditions. The highest accuracy was observed in hydrocele and abscess cases, both showing 100% diagnostic accuracy. Testicular torsion demonstrated a high accuracy of 90.9%, indicating reliable detection using Doppler imaging. Epididymo-orchitis showed an accuracy of 86.4%, while trauma cases had slightly lower accuracy at 85.7%, likely due to variability in presentation. Overall, ultrasonography proved to be a highly sensitive and dependable modality for diagnosing scrotal emergencies.

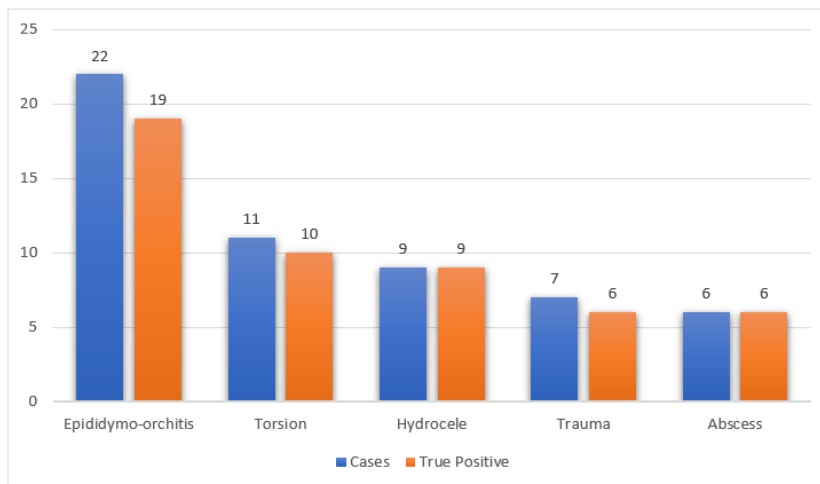


Figure 2: Diagnostic Accuracy

Table 4: Testicular Salvage Rates

Time to Diagnosis	Salvage Rate
<6 hours	90%
6–12 hours	50%
>24 hours	<10%

Table 4 depicts the relationship between time to diagnosis and testicular salvage rates in cases of testicular torsion. The highest salvage rate (90%) was observed when diagnosis and intervention occurred within 6 hours of symptom onset. This rate decreased to 50% when treatment was delayed to 6–12 hours and dropped drastically to less than 10% after 24 hours. These findings emphasize the critical importance of early diagnosis and timely management in improving testicular viability.

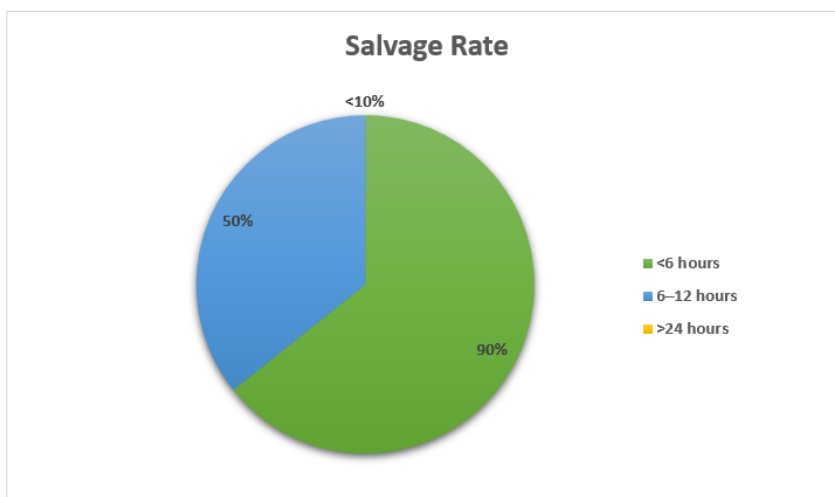


Figure 3: Testicular Salvage Rates

DISCUSSION

Scrotal emergencies represent a diagnostic challenge due to overlapping clinical presentations and the need for rapid differentiation between surgical and

non-surgical conditions. The current study found that ultrasonography with Color Doppler was a valid and efficient method for assessing acute scrotal diseases. Testicular torsion (24%) and hydrocele (18%) were the

next most prevalent conditions in this investigation, with epididymo-orchitis accounting for 44% of cases (Table 1). These results are in line with other research showing that, especially in adult populations, inflammatory diseases constitute the most common cause of acute scrotum [6,7]. Delays in obtaining medical attention and infectious etiologies may be responsible for the prevalence of epididymo-orchitis.

The clinical significance of testicular torsion as a surgical emergency is shown by the fact that it accounted for 24% of cases (Table 1). Existing literature provides strong support for ultrasonographic results such as an enlarged hypoechoic testis and lacking vascularity found in this investigation [8]. Even though it cannot be measured independently, the whirlpool sign is nonetheless a very specific sonographic characteristic of torsion and is essential for early diagnosis [9]. The ultrasonographic characteristics listed in Table 2 show how well imaging may distinguish between different scrotal disorders. A clear differentiation is provided by increased vascularity in epididymo-orchitis and lack flow in torsion, which is sometimes challenging to do clinically. Studies highlighting the diagnostic advantage of Doppler ultrasonography in acute scrotum examination have revealed similar results [10,11].

In this investigation, good diagnostic accuracy was found in all situations. Testicular torsion had an accuracy of 90.9%, but hydrocele and abscess showed 100% accuracy, as Table 3 illustrates. The accuracy rates for trauma and epididymo-orchitis were somewhat lower, with 85.7% and 86.4%, respectively. These results are consistent with other studies that showed Doppler ultrasonography in scrotal crises to have sensitivity and specificity values greater than 85–90% [11,12]. The varied character of injuries and related results may be the cause of the comparatively reduced accuracy in trauma cases.

The effect of early detection on testicular salvage is one of the study's most important findings. Table 4 illustrates that the salvage rate peaked at 90% when intervention took place within 6 hours, fell to 50% between 6 and 12 hours, and then fell to less than 10% after 24 hours. These findings are consistent with previous research that highlights the limited window of time for testicular viability in torsion situations [8,13]. This emphasizes how crucial timely imaging and rapid clinical decision-making are. The prevalence of inflammatory diseases, the excellent diagnostic accuracy of ultrasonography, and the time-dependent drop in salvage rates are further highlighted by the graphical representations (Figures 1-3). These results support the use of ultrasonography as an initial imaging technique for acute scrotal diseases.

The decrease in needless surgical probing is another significant aspect of this study. Using ultrasonography to accurately distinguish between surgical and non-surgical problems helps prevent unfavorable investigations and

guarantees the right course of therapy. Recent studies that highlight better patient outcomes and less healthcare burden with early imaging have demonstrated similar advantages [12]. Ultrasonography has certain drawbacks despite its benefits, such as operator dependence and decreased sensitivity in early or sporadic torsion. It is still the most useful and trustworthy diagnostic method in emergency situations, nevertheless, when paired with clinical assessment. Overall, because of its excellent diagnostic accuracy, quick availability, and non-invasive nature, the results of this study clearly support the use of ultrasonography with Color Doppler as the preferred imaging modality in scrotal crises.

CONCLUSION

Ultrasonography with Color Doppler is an indispensable tool in the evaluation of scrotal emergencies. This study demonstrates that it is a rapid, non-invasive, and highly accurate diagnostic modality that effectively differentiates surgical conditions such as testicular torsion from non-surgical causes like epididymo-orchitis and hydrocele. Doppler ultrasonography's capacity to measure vascularity is essential for early diagnosis, especially in situations of torsion when prompt treatment decides testicular survivability. The results of the study demonstrate that testicular salvage rates are greatly increased by early ultrasonographic examination, which also lowers the risk of consequences like infertility. Additionally, by precisely diagnosing non-surgical illnesses, ultrasonography eliminates needless surgical treatments, improving patient care and lowering the cost of healthcare. It is the first-line imaging modality in acute scrotal diseases because, despite a few minor limitations, its benefits greatly exceed its disadvantages. In summary, timely application of ultrasonography in scrotal crises is critical for precise diagnosis, suitable treatment, and better clinical results.

REFERENCES

1. Boettcher M, Bergholtz GL, Wendt H, et al. Clinical and ultrasound predictors for testicular torsion versus epididymitis in children. *J Urol*. 2012;188(4):1310–1315.
2. Medscape. Epididymitis Imaging.
3. Smith JM, Jones B. Role of ultrasonography in diagnosis of scrotal disorders. *Biomed Imaging Interv J*. 2009;5(2):e14.
4. Middleton WD, et al. Color Doppler ultrasound of the scrotum. *AJR*. 1989;152:293–297.
5. Dogra VS, et al. Sonography of the scrotum. *Radiology*. 2003;227(1):18–36.
6. Trojian TH, Lishnak TS, Heiman D. Epididymitis and orchitis: an overview. *Am Fam Physician*. 2009;79(7):583–587.
7. Nickel JC, Siemens DR, Nickel KR, Downey J. The patient with chronic epididymitis: characterization of an enigmatic syndrome. *J Urol*. 2002;167(4):1701–1704.

8. Cummings JM, Boullier JA. The accuracy of Doppler ultrasound in the diagnosis of testicular torsion. *J Urol*. 2002;168(4):1589–1592.
9. Kalfa N, Veyrac C, Lopez M, et al. Multicenter assessment of ultrasound of the spermatic cord in children with testicular torsion. *J Urol*. 2007;177(1):297–301.
10. Bhatt S, Dogra VS. Role of US in testicular and scrotal trauma. *Radiographics*. 2008;28(6):1617–1629.
11. Pepe P, Panella P, Pennisi M, Aragona F. Does color Doppler sonography improve the clinical assessment of patients with acute scrotum? *Eur J Radiol*. 2006;60(1):120–124.
12. Lewis AG, Bukowski TP, Jarvis PD, et al. Evaluation of acute scrotum in the emergency department. *J Pediatr Surg*. 1995;30(2):277–281.
13. Kapoor S. Testicular torsion: a race against time. *Int J Clin Pract*. 2008;62(5):821–827.