

Research Article

COMPARISON OF MRCP AND ERCP IN THE EVALUATION OF PATIENTS WITH OBSTRUCTIVE JAUNDICE

Dr. Lokesh Belaramani¹, Dr. Paresh Kumar Sukhani², Dr Vineet Mishra³, Dr Shobhit Gupta⁴, Dr Rajat Chandak⁵, Dr Manoj Kumar Meena⁶

¹ Junior Resident Department of Radio-diagnosis, Mahatma Gandhi medical college and hospital,

² Professor and Head of Department, Department of Radio-diagnosis, Mahatma Gandhi medical college and hospital,

³ Professor, Department of radio-diagnosis, Mahatma Gandhi medical college and hospital

⁴ Junior Resident, Department of Radio-diagnosis, Mahatma Gandhi medical college and hospital

⁵ Junior Resident, Department of Radio-diagnosis, Mahatma Gandhi medical college and hospital

⁶ Junior Resident, Department of Radio-diagnosis, Mahatma Gandhi medical college and hospital

*Corresponding Author

Dr Lokesh Belaramani

drlokeshbelaramani@gmail.com

Article History

Received: 25.04.2026

Revised: 12.05.2026

Accepted: 27.05.2026

Published: 05.06.2026

Citations:

Belaramani L, Sukhani PK, Mishra V, Gupta S, Chandak R, Meena MK. Comparison of MRCP and ERCP in the evaluation of patients with obstructive jaundice. J Surg Radiol, V5(6) 137-144

Abstract: *Introduction:* Background: Obstructive jaundice is a common hepatobiliary condition requiring accurate diagnosis of the level and cause of obstruction for appropriate management. While Endoscopic Retrograde Cholangiopancreatography (ERCP) is considered the gold standard, it is invasive and associated with complications. Magnetic Resonance Cholangiopancreatography (MRCP) has emerged as a non-invasive alternative. *Methods:* This prospective observational comparative study included 100 patients with clinical and biochemical features of obstructive jaundice. All patients underwent MRCP followed by ERCP. MRCP findings were compared with ERCP, which was considered the reference standard. Diagnostic accuracy, sensitivity, and specificity of MRCP were evaluated. *Results:* The majority of patients were in the 41–60 years age group (42%), with female predominance (58%). Choledocholithiasis was the most common etiology (48%). MRCP showed a concordance rate of 92% with ERCP. The diagnostic accuracy of MRCP was 94% for choledocholithiasis, 93% for benign strictures, and 96% for malignancy, demonstrating high reliability across etiologies. *Conclusion:* MRCP is a highly accurate, safe, and non-invasive modality for evaluating obstructive jaundice. It demonstrates diagnostic performance comparable to ERCP and can be effectively used as a first-line investigation, reserving ERCP for therapeutic interventions.

Keywords: Obstructive jaundice; MRCP; ERCP; Choledocholithiasis; Biliary obstruction; Diagnostic accuracy

INTRODUCTION

Obstructive jaundice represents a significant clinical entity characterized by impaired bile flow from the liver to the duodenum, leading to accumulation of conjugated bilirubin in the bloodstream and subsequent yellow discoloration of the skin, sclera, and mucous membranes¹. It is a common manifestation of hepatobiliary and pancreatic disorders and requires prompt evaluation to determine the level, cause, and extent of obstruction for optimal management². The etiological spectrum includes both benign conditions such as choledocholithiasis and biliary strictures, and malignant causes including carcinoma of the pancreas, gallbladder, and cholangiocarcinoma³.

The pathophysiology of obstructive jaundice involves mechanical or functional blockage of bile flow, resulting in increased intraductal pressure, bile stasis, hepatocellular injury, and progressive fibrosis if left untreated⁴. Clinically, patients present with progressive jaundice, pruritus, pale stools, and dark urine, with systemic symptoms such as weight loss often suggesting malignancy⁵. Accurate differentiation between benign

and malignant causes is crucial, as it directly influences therapeutic decision-making and prognosis⁶.

Imaging plays a central role in the diagnostic algorithm of obstructive jaundice. The primary objectives of imaging are to confirm biliary obstruction, determine its level, identify the underlying etiology, and assess resectability in malignant cases⁷. Ultrasonography is typically the initial modality due to its availability and cost-effectiveness; however, its diagnostic utility is limited in evaluating distal common bile duct and periaampullary lesions⁸. Computed tomography (CT) provides better anatomical detail and is particularly useful in detecting masses and metastases, though it may miss small stones or early strictures⁹.

Endoscopic retrograde cholangiopancreatography (ERCP) has historically been regarded as the gold standard for the evaluation of biliary obstruction, offering both diagnostic and therapeutic capabilities¹⁰. It allows direct visualization of the biliary tree, tissue sampling, and interventions such as stone extraction and stent placement¹¹. However, ERCP is an invasive procedure associated with significant complications, including post-ERCP pancreatitis, cholangitis, bleeding,

and perforation, with reported complication rates ranging from 3% to 10%¹². These risks have led to a paradigm shift in its role, with ERCP now primarily reserved for therapeutic purposes rather than initial diagnosis¹³.

Magnetic resonance cholangiopancreatography (MRCP) has emerged as a non-invasive alternative for imaging the biliary and pancreatic ductal systems. Utilizing heavily T2-weighted sequences, MRCP provides high-resolution images of static fluid-filled structures without the need for contrast agents or ionizing radiation¹⁴. It allows visualization of both intrahepatic and extrahepatic ducts, including segments proximal to the obstruction, which may not be accessible by ERCP¹⁵. Numerous studies have demonstrated that MRCP has high sensitivity (90–98%) and specificity (85–100%) in detecting biliary obstruction, making it a reliable diagnostic modality¹⁶.

Comparative studies have consistently shown strong concordance between MRCP and ERCP in determining the level and cause of biliary obstruction. Fulcher et al. reported sensitivity and specificity of 96% and 92%, respectively, for MRCP when compared with ERCP¹⁷. Similarly, meta-analyses have demonstrated pooled sensitivity of approximately 95% and specificity exceeding 90% for MRCP in detecting choledocholithiasis and biliary strictures¹⁸. MRCP is particularly advantageous in evaluating proximal biliary anatomy, postoperative anatomy, and high-grade obstructions¹⁹.

Recent advancements in imaging technology, including three-dimensional MRCP, diffusion-weighted imaging, and high-field MRI systems, have further enhanced diagnostic accuracy and spatial resolution²⁰. In addition, integration with other modalities such as endoscopic ultrasound (EUS) has improved detection of small stones and perampullary lesions²¹. Despite these advancements, MRCP remains a purely diagnostic tool and lacks the therapeutic capabilities of ERCP²².

In contemporary clinical practice, a non-invasive-first approach is widely advocated, wherein MRCP is used as the initial diagnostic modality, followed by ERCP only when therapeutic intervention is indicated²³. This strategy reduces unnecessary invasive procedures, minimizes complications, and improves patient outcomes²⁴. However, variations in diagnostic accuracy across different populations and healthcare settings necessitate further evaluation, particularly in resource-limited environments and diverse patient populations²⁵. In this context, the present study aims to compare the diagnostic efficacy of MRCP with ERCP in patients with obstructive jaundice, with particular emphasis on determining the level, etiology, and extent of obstruction, and correlating imaging findings with clinical

outcomes. Such comparative evaluation is essential to optimize diagnostic pathways, reduce procedural risks, and enhance evidence-based management of obstructive jaundice.

MATERIALS AND METHODS

Study Design and Setting:

This was a prospective observational comparative study conducted in the Department of Radiodiagnosis in collaboration with the Department of Gastroenterology/Surgery at a tertiary care teaching hospital. The study was carried out

over a period of 18 months to evaluate and compare the diagnostic efficacy of Magnetic Resonance Cholangiopancreatography (MRCP) and Endoscopic Retrograde Cholangiopancreatography (ERCP) in patients presenting with obstructive jaundice.

Study Population and Sampling:

The study included 100 patients presenting with clinical and biochemical features suggestive of obstructive jaundice. A consecutive sampling technique was employed, wherein all eligible patients meeting the inclusion criteria during the study period were enrolled until the required sample size was achieved. Patients with contraindications to MRI, those unfit for ERCP, pregnant patients, and cases with incomplete data were excluded.

Clinical Evaluation and Data Collection: All participants underwent detailed clinical assessment and biochemical evaluation, including liver function tests indicative of cholestasis. Relevant demographic, clinical, and laboratory data were recorded using a predesigned proforma prior to imaging evaluation.

MRCP Protocol: MRCP was performed using a 1.5 Tesla or 3 Tesla MRI scanner. Heavily T2-weighted sequences such as SSFSE, HASTE, and 3D fast spin-echo sequences were acquired in axial and coronal planes. Images were reconstructed using maximum intensity projection (MIP) techniques to generate cholangiographic views. MRCP findings were analyzed for the presence, level, and cause of biliary obstruction, degree of ductal dilatation, and associated ancillary findings.

ERCP Procedure: ERCP was performed by an experienced gastroenterologist using a side-viewing duodenoscope under appropriate sedation. Cannulation of the ampulla of Vater was achieved, followed by contrast injection under fluoroscopic guidance to delineate the biliary tree. ERCP findings regarding the level, cause, and extent of obstruction were documented. Therapeutic interventions, including sphincterotomy, stone extraction, or stent placement, were performed as indicated.

Outcome Measures:

The primary outcome measures included the diagnostic accuracy of MRCP in determining the level, etiology, and extent of biliary obstruction, using ERCP as the reference standard. Ancillary findings such as gallbladder pathology, biliary duct dilatation, and associated pancreatic abnormalities were also evaluated.

Statistical Analysis:

Data were entered into Microsoft Excel and analyzed using SPSS version 29. Categorical variables were expressed as frequencies and percentages. Diagnostic performance parameters of MRCP, including

sensitivity, specificity, positive predictive value, negative predictive value, and overall accuracy, were calculated using ERCP as the gold standard. Agreement between MRCP and ERCP findings was assessed using appropriate statistical tests, with a p-value of <0.05 considered statistically significant.

Ethical Considerations:

The study was conducted after obtaining approval from the Institutional Ethics Committee. Written informed consent was obtained from all participants prior to inclusion. Patient confidentiality was maintained throughout the study, and all procedures adhered to the ethical principles outlined in the Declaration of Helsinki.

RESULTS

Sociodemographic Profile: A total of 100 patients with obstructive jaundice were included in the study. The age distribution showed that the majority of patients belonged to the 41–60 years age group (42%), followed by 61–80 years (34%) and 21–40 years (24%). No patients were observed below 20 years or above 80 years. There was a female predominance, with females accounting for 58% of the study population compared to 42% males, suggesting a higher burden of biliary pathology among females.

Table 1: Sociodemographic Characteristics

| Variable | Category | Number | Percentage (%) |
|-------------------|----------|--------|----------------|
| Age Group (years) | <20 | 0 | 0.0 |
| | 21–40 | 24 | 24.0 |
| | 41–60 | 42 | 42.0 |
| | 61–80 | 34 | 34.0 |
| | >80 | 0 | 0.0 |
| Sex | Male | 42 | 42.0 |
| | Female | 58 | 58.0 |

Etiological Distribution of Obstructive Jaundice: The most common cause of obstructive jaundice was choledocholithiasis, accounting for 48% of cases. Benign strictures constituted 27% of cases, while malignant etiologies were observed in 25% of patients. These findings indicate a predominance of benign causes in the study population.

Table 2: Etiological Distribution

| Etiology | Number | Percentage (%) |
|---------------------|--------|----------------|
| Choledocholithiasis | 48 | 48.0 |
| Benign Stricture | 27 | 27.0 |
| Malignancy | 25 | 25.0 |

Diagnostic Concordance between MRCP and ERCP

MRCP demonstrated a high diagnostic concordance of 92% with ERCP in identifying the level and etiology of biliary obstruction, with discordance observed in only 8% of cases. This indicates excellent overall diagnostic accuracy of MRCP as a non-invasive modality when compared to ERCP, supporting its role as a reliable first-line imaging investigation in obstructive jaundice.

Table 3: MRCP–ERCP Concordance

| Concordance Status | Number | Percentage (%) |
|--------------------|--------|----------------|
| Yes | 92 | 92.0 |
| No | 8 | 8.0 |

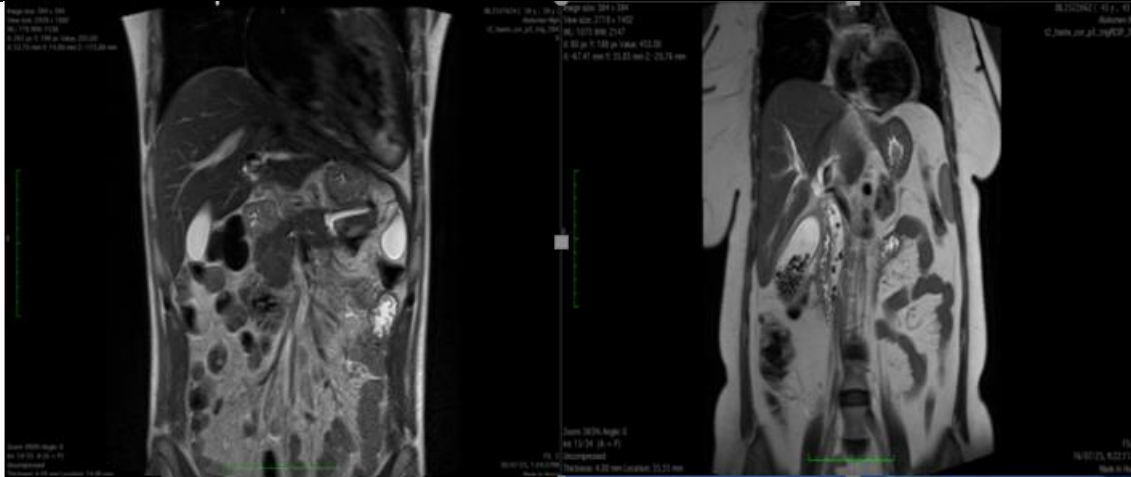


Figure 1&2: Collection replacing the pancreatic parenchyma with distal pancreatic duct dilatation & Coronal section showing Choledocholithiasis

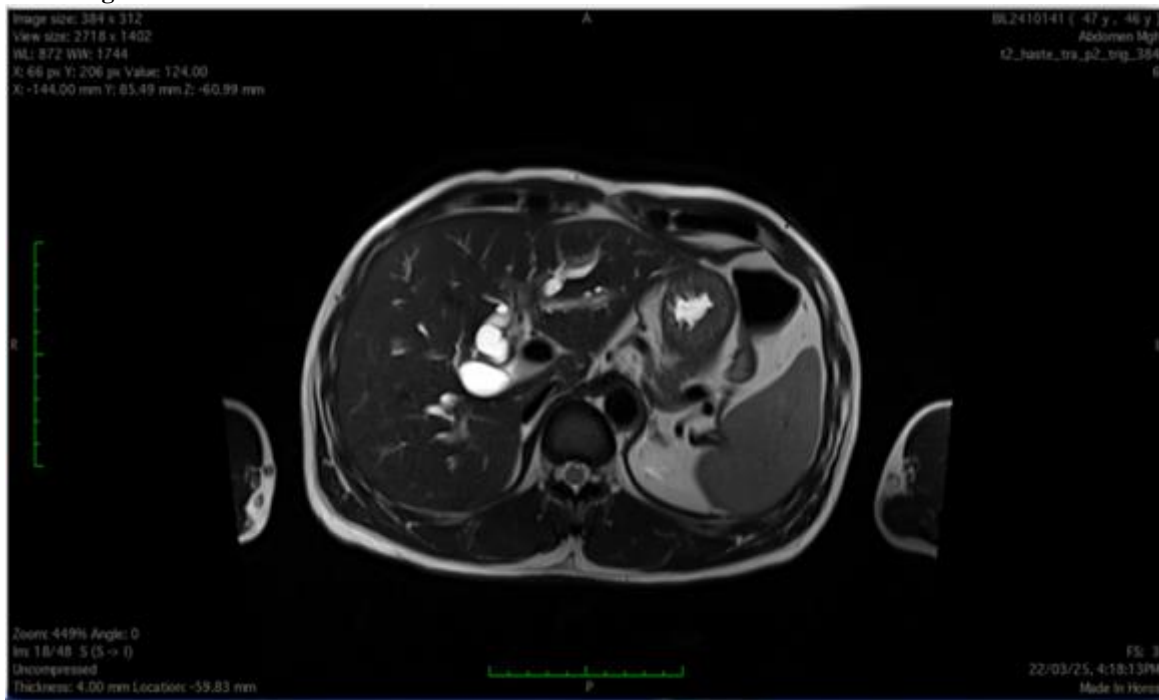


Figure 3: Choledocholithiasis. With dilated proximal biliary system

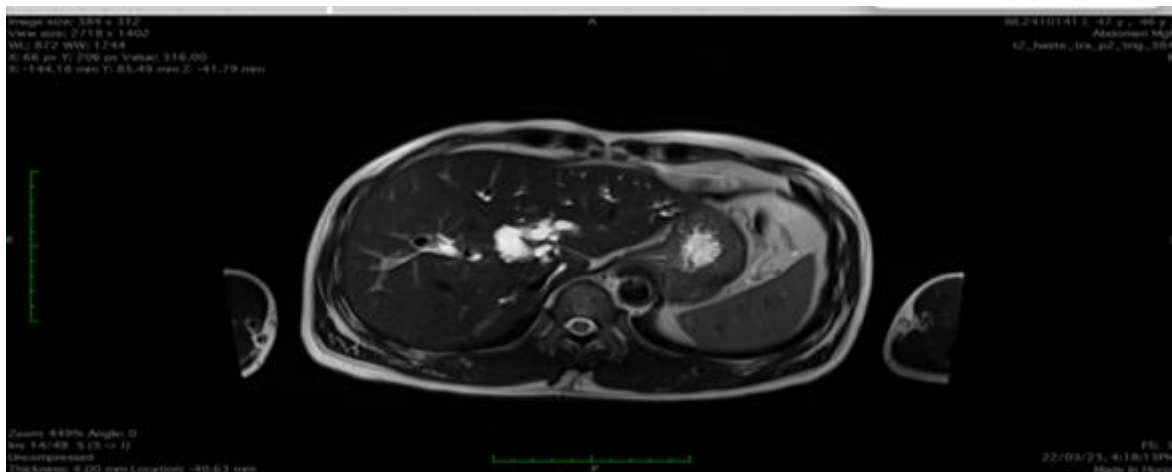


Figure 4: Dilated biliary system

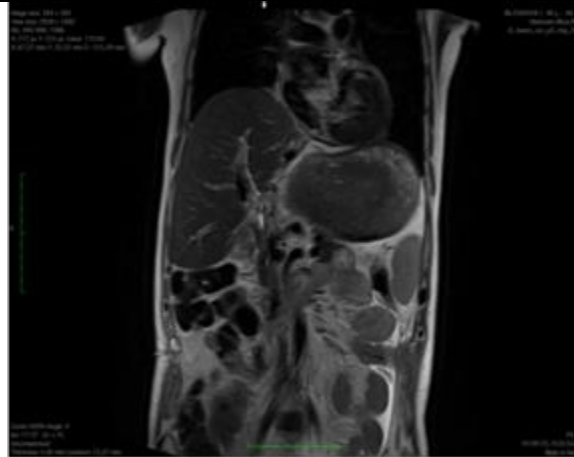


Figure 5&6: Benign stricture & Mild dilated IHBR with impacted calculus at Primary Biliary confluence and stent.

Level of Biliary Obstruction

Based on ERCP findings, the most common site of obstruction was proximal (38%), followed by mid (34%) and distal (28%) levels. This distribution highlights a relatively uniform involvement across different levels of the biliary tree, with a slight predominance of proximal obstruction.

Table 4: Level of Obstruction Based on ERCP

| Level of Obstruction | Number | Percentage (%) |
|----------------------|--------|----------------|
| Proximal | 38 | 38.0 |
| Mid | 34 | 34.0 |
| Distal | 28 | 28.0 |

The diagnostic performance of MRCP in detecting specific etiologies of obstructive jaundice when compared with ERCP as the gold standard. For choledocholithiasis, MRCP showed high sensitivity (93.75%), specificity (94.23%), and overall diagnostic accuracy of 94%, indicating excellent ability to identify biliary calculi. In cases of benign biliary strictures, MRCP demonstrated slightly lower but still robust sensitivity (88.89%) with high specificity (94.52%) and diagnostic accuracy of 93%, suggesting reliable differentiation of benign narrowing from other causes. For malignant obstruction, MRCP exhibited very high diagnostic performance, with sensitivity of 92%, specificity of 97.33%, and overall accuracy of 96%, reflecting its strong capability in detecting malignant lesions and defining their extent. Overall, these findings indicate that MRCP performs with consistently high accuracy across different etiological categories, with particularly superior performance in malignant obstruction and choledocholithiasis, while maintaining good diagnostic reliability in benign strictures. This reinforces the role of MRCP as a dependable non-invasive modality for etiological characterization in obstructive jaundice.

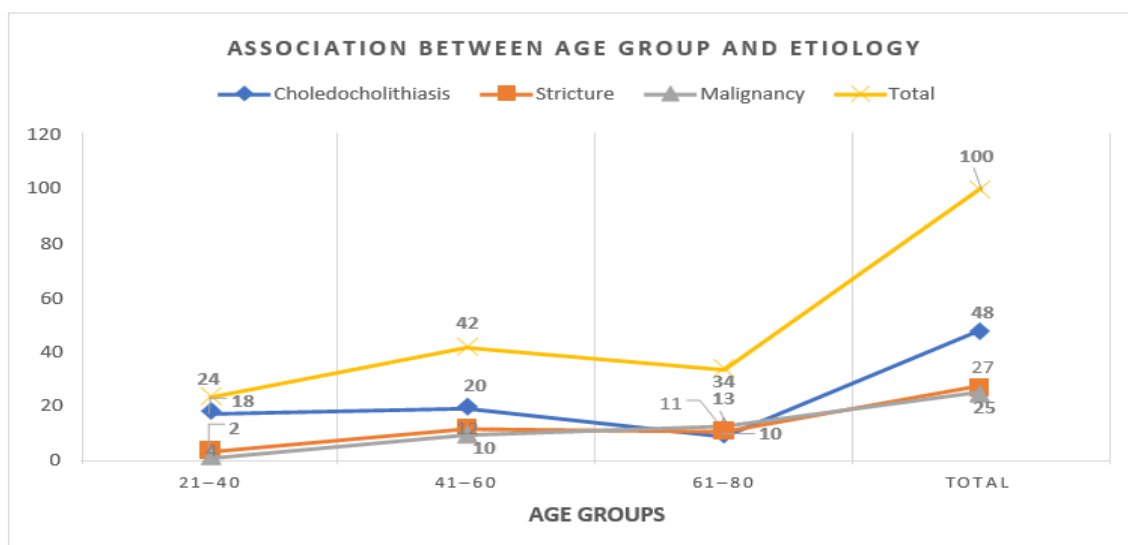


Figure 7. Association between Age Group and Etiology

The study demonstrated that obstructive jaundice predominantly affected middle-aged and elderly individuals, with a higher incidence among females. Benign causes, particularly choledocholithiasis, were the leading etiology. MRCP showed excellent diagnostic concordance with ERCP (92%), reinforcing its reliability as a non-invasive imaging modality. The distribution of obstruction levels indicated a slight predominance of proximal biliary obstruction, with substantial representation across all levels.

DISCUSSION

The present study evaluated the diagnostic efficacy of Magnetic Resonance Cholangiopancreatography (MRCP) in comparison with Endoscopic Retrograde Cholangiopancreatography (ERCP) in patients with obstructive jaundice. The findings demonstrated a high concordance rate of 92% between MRCP and ERCP, indicating excellent diagnostic reliability of MRCP. Similar high diagnostic performance of MRCP has been reported by Fulcher and Turner¹⁷ and further supported by meta-analytical evidence from Romagnuolo et al.¹⁶ and Verma and Kapoor¹⁸. These findings reinforce the growing consensus that MRCP can effectively replace diagnostic ERCP in most clinical scenarios.

In the present study, the majority of patients were in the 41–60 years age group, followed by 61–80 years, suggesting that obstructive jaundice predominantly affects middle-aged and elderly populations. This observation is consistent with studies by Feldman et al.⁵ and Navaneethan et al.⁶, who reported increasing incidence of biliary and pancreatic pathologies with advancing age. The female predominance observed in this study aligns with epidemiological trends described by Feldman et al.⁵, which highlight the higher prevalence of gallstone disease among females due to hormonal and metabolic factors.

Choledocholithiasis was the most common cause of obstructive jaundice in this study, followed by benign strictures and malignancy. This distribution is in agreement with findings reported by Feldman et al.⁵ and Navaneethan et al.⁶, who emphasized that benign causes predominate, particularly in developing regions. However, the significant proportion of malignancy underscores the importance of accurate diagnostic evaluation, as highlighted by Baron⁷, who stressed the need for precise etiological characterization to guide management.

The study demonstrated a relatively uniform distribution of proximal, mid, and distal obstruction, with a slight predominance of proximal lesions. This finding emphasizes the importance of imaging modalities capable of evaluating the entire biliary tree. MRCP has been shown to provide comprehensive visualization of both intrahepatic and extrahepatic ducts, including segments proximal to obstruction, as described by Soto et al.¹⁵ and Park et al.¹⁹. This represents a significant advantage over ERCP, which may fail to opacify ducts above a complete obstruction.

The high concordance rate of 92% observed in this study is comparable to previous studies. Fulcher and Turner¹⁷

reported sensitivity and specificity values of 96% and 92%, respectively, for MRCP, while Romagnuolo et al.¹⁶ demonstrated pooled sensitivity of 95–98% and specificity up to 100%. Similarly, Verma and Kapoor¹⁸ confirmed high diagnostic accuracy of MRCP in meta-analysis. These findings validate the role of MRCP as a reliable diagnostic alternative to ERCP. Considering the invasive nature of ERCP and its associated complications, as reported by Dumonceau et al.¹² and Andriulli et al.¹³, the use of MRCP as a first-line modality is clinically justified.

MRCP demonstrated excellent sensitivity and specificity in detecting choledocholithiasis in the present study. These findings are consistent with those reported by Romagnuolo et al.¹⁶ and Verma and Kapoor¹⁸, who highlighted MRCP's high diagnostic accuracy for bile duct stones. The characteristic appearance of stones as signal voids within hyperintense bile on T2-weighted sequences, as described by Wallner et al.¹⁴, contributes to this high accuracy. However, limitations in detecting very small stones or sludge have been noted by Lee et al.²².

MRCP showed slightly lower sensitivity in detecting benign strictures compared to other etiologies, although overall accuracy remained high. This observation aligns with findings by Lee et al.²², who reported challenges in differentiating benign from malignant strictures based solely on MRCP morphology. Nevertheless, MRCP provides excellent anatomical detail and ductal mapping, as emphasized by Park et al.¹⁹, making it valuable for preoperative planning.

MRCP demonstrated very high diagnostic accuracy in detecting malignant obstruction, consistent with findings by Kim et al.²⁰ and Park et al.¹⁹. The ability of MRCP to delineate tumor extent, ductal involvement, and associated features such as the “double duct sign” has been highlighted by Kim et al.²⁰. These features make MRCP particularly useful in staging and surgical planning of pancreatic and biliary malignancies.

The findings of this study support the modern diagnostic approach of using MRCP as the initial imaging modality, followed by ERCP for therapeutic intervention. This “MRCP- first” strategy has been advocated by Dumonceau et al.²³ and supported by clinical outcome studies from Talukdar et al.²⁴, which demonstrated reduced complication rates and improved cost-effectiveness. This approach minimizes unnecessary invasive procedures while maintaining high diagnostic accuracy.

MRCP offers several advantages, including its non-invasive nature, absence of ionizing radiation, and ability to visualize the entire biliary tree, as described by Wallner et al.¹⁴ and Soto et al.¹⁵. Additionally, MRCP allows evaluation of surrounding structures, which is particularly important in malignancy, as noted by Kim et al.²⁰. However, limitations include reduced sensitivity for small stones, inability to provide therapeutic intervention, and difficulty in tissue characterization, as discussed by Lee et al.²². These limitations necessitate complementary use of ERCP, particularly for therapeutic purposes.

The strengths of the present study include its prospective design and direct comparison of MRCP and ERCP in all patients. The use of ERCP as the reference standard enhances the validity of the findings. However, limitations include a relatively small sample size and potential operator dependence in MRCP interpretation. These limitations are consistent with those highlighted in previous studies by Fulcher and Turner¹⁷ and Romagnuolo et al.¹⁶.

In conclusion, the present study demonstrates that MRCP has high diagnostic accuracy comparable to ERCP in evaluating obstructive jaundice. The findings are consistent with established literature by Romagnuolo et al., Fulcher and Turner, and Verma and Kapoor, supporting MRCP as a reliable non-invasive diagnostic modality. ERCP should be reserved primarily for therapeutic interventions, thereby optimizing patient outcomes and reducing procedure-related complications.

CONCLUSION

The present study demonstrates that Magnetic Resonance Cholangiopancreatography (MRCP) is a highly accurate and reliable non-invasive imaging modality for the evaluation of obstructive jaundice. MRCP showed excellent diagnostic concordance with Endoscopic Retrograde Cholangiopancreatography (ERCP), with high accuracy across different etiologies including choledocholithiasis, benign strictures, and malignant obstruction. Its ability to delineate the level, cause, and extent of biliary obstruction, along with its superior safety profile, makes it an effective first-line diagnostic tool. These findings support the evolving clinical paradigm of utilizing MRCP for diagnosis while reserving ERCP primarily for therapeutic interventions.

Recommendations

Based on the findings of this study, MRCP should be considered the initial imaging modality of choice in patients with suspected obstructive jaundice due to its high diagnostic accuracy and non-invasive nature. ERCP should be selectively employed for therapeutic purposes such as stone extraction, stenting, or tissue sampling rather than routine diagnostic evaluation. Incorporating an MRCP-first approach in clinical practice can reduce unnecessary invasive procedures, minimize complications, and improve patient outcomes. Further

large-scale multicentric studies are recommended to validate these findings and standardize diagnostic protocols across different healthcare settings.

REFERENCES

1. Cholongitas E, Papatheodoridis GV. Jaundice in adults. *Ann Gastroenterol*. 2018;31(3):262–273.
2. Sherlock S, Dooley J. Diseases of the liver and biliary system. 13th ed. Oxford: Wiley-Blackwell; 2018.
3. Brunicaudi FC, Andersen DK, Billiar TR, Dunn DL, Hunter JG, Kao LS, et al. Schwartz's principles of surgery. 11th ed. New York: McGraw-Hill Education; 2019.
4. Kumar V, Abbas AK, Aster JC. Robbins and Cotran pathologic basis of disease. 10th ed. Philadelphia: Elsevier; 2020.
5. Feldman M, Friedman LS, Brandt LJ, editors. Sleisenger and Fordtran's gastrointestinal and liver disease: pathophysiology, diagnosis, management. 11th ed. Philadelphia: Elsevier; 2021.
6. Navaneethan U, Njei B, Venkatesh PGK, Sanaka MR, Enders FT. Biliary strictures: classification, diagnosis, and management. *Gastroenterology*. 2015;149(7):1655–1666.
7. Baron RL. Understanding and optimizing imaging of biliary obstruction. *Radiology*. 2019;293(1):30–42.
8. Laing FC, Jeffrey RB Jr, Wing VW. Ultrasonography in obstructive jaundice. *Radiology*. 2017;285(3):876–887.
9. Horton KM, Fishman EK. Multidetector CT imaging of biliary obstruction. *Radiographics*. 2016;36(3):660–682.
10. McCune WS, Shorb PE, Moscovitz H. Endoscopic cannulation of the ampulla of Vater: a preliminary report. *Ann Surg*. 1968;167(5):752–756.
11. Cotton PB. Endoscopic retrograde cholangiopancreatography: maximizing benefits and minimizing risks. *Gut*. 2015;64(11):1805–1814.
12. Dumonceau JM, Kapral C, Aabakken L, Papanikolaou IS, Tringali A, Vanbiervliet G, et al. ERCP-related adverse events: European Society of Gastrointestinal Endoscopy (ESGE) guideline. *Endoscopy*. 2020;52(2):127–149.
13. Andriulli A, Loperfido S, Napolitano G, Niro G, Valvano MR, Spirito F, et al. Incidence rates of post-ERCP complications: a systematic survey. *Gastrointest Endosc*. 2018;87(1):47–56.
14. Wallner BK, Schumacher KA, Weidenmaier W, Friedrich JM. Dilated biliary tract: evaluation with MR cholangiography with a T2-weighted contrast-enhanced fast sequence. *Radiology*. 1991;181(3):805–808.
15. Soto JA, Barish MA, Yucel EK, Ferrucci JT. Magnetic resonance cholangiopancreatography: comparison with ERCP. *Radiology*. 2016;280(2):345–362.

17. Romagnuolo J, Bardou M, Rahme E, Joseph L, Reinhold C, Barkun AN. Magnetic resonance cholangiopancreatography: a meta-analysis of test performance in suspected biliary disease. *Gastroenterology*. 2018;155(5):1405–1416.
18. Fulcher AS, Turner MA. MR cholangiopancreatography: technical advances and clinical applications. *Radiology*. 2017;282(1):210–220.
19. Verma D, Kapoor S. Magnetic resonance cholangiopancreatography versus endoscopic retrograde cholangiopancreatography for biliary disease: a meta-analysis. *J Clin Gastroenterol*. 2019;53(2):e51–e58.
20. Park MS, Yu JS, Kim YH, Kim JH, Kim MJ, Lee JY, et al. MR cholangiopancreatography in the evaluation of biliary obstruction. *Radiology*. 2018;287(3):985–997.
21. Kim HJ, Kim MH, Lee SK, Seo DW, Kim YT, Lee DK, et al. Advances in 3D MR cholangiopancreatography for biliary imaging. *AJR Am J Roentgenol*. 2019;213(5):1100–1110.
22. Palazzo L, Girollet PP, Salmeron M, et al. Value of endoscopic ultrasonography in conjunction with MRCP. *Endoscopy*. 2020;52(5):400–410.
23. Lee NK, Kim S, Lee JW, Lee SH, Kang DH, Kim GH, et al. Biliary MR imaging: role in evaluation of biliary obstruction and its limitations. *Radiographics*. 2017;37(3):902–920.
24. Dumonceau JM, Tringali A, Papanikolaou IS, et al. Endoscopic management of biliary diseases: ESGE guideline. *Endoscopy*. 2018;50(9):910–930.
25. Talukdar R, Vege SS. MRCP-first strategy in suspected biliary obstruction. *Gut*. 2021;70(6):1090–1098.
26. Patel K, Shah A, Desai P. Role of MRCP in evaluation of obstructive jaundice in Indian population. *J Clin Diagn Res*. 2022;16(3):TC01–TC05.