

## Research Article

# Role of Ultrasonography and Colour Doppler in the Evaluation of Portal Hypertension

<sup>1</sup>Dr. Sharbeen Waqar, <sup>2</sup>Dr. Kuldeep Kumar Mendiratta, <sup>3</sup>Dr Pawan Kalwaniya, <sup>4</sup>Dr Bhavya Chaudhry, <sup>5</sup>Dr Sarthak Chandra, <sup>6</sup>Dr Paresh Kumar Sukhani

<sup>1</sup> Junior Resident, Department of Radiodiagnosis, Mahatma Gandhi Medical College & Hospital Jaipur, Rajasthan

<sup>2</sup> Professor, Department of Radiodiagnosis, Mahatma Gandhi Medical College & Hospital Jaipur, Rajasthan

<sup>3</sup> Junior Resident, Department of Radiodiagnosis, Mahatma Gandhi Medical College & Hospital Jaipur, Rajasthan

<sup>4</sup> Junior Resident, Department of Radiodiagnosis, Mahatma Gandhi Medical College & Hospital Jaipur, Rajasthan

<sup>5</sup> Junior Resident, Department of Radiodiagnosis, Mahatma Gandhi Medical College & Hospital Jaipur, Rajasthan

<sup>6</sup> Professor, Department of Radiodiagnosis, Mahatma Gandhi Medical College & Hospital Jaipur, Rajasthan

### \*Corresponding Author

A

#### Article History

**Received:** 15.05.2026

**Revised:** 25.05.2026

**Accepted:** 31.05.2026

**Published:** 05.06.2026

#### Citations:

Waqar, S., Mendiratta, K. K., Kalwaniya, P., Chaudhry, B., Chandra, S., & Sukhani, P. K. (n.d.). Role of ultrasonography and colour Doppler in the evaluation of portal hypertension. *J Surg Radiol*, V5(6) 145-155

**Abstract:** **Introduction:** Portal hypertension is a major complication of chronic liver disease and is associated with ascites, splenomegaly, collateral formation, and variceal bleeding. Ultrasonography with color Doppler provides a non-invasive and readily available method for evaluating portal venous hemodynamics. **Aim:** To evaluate the role of ultrasonography and color Doppler in patients with portal hypertension. **Materials and Methods:** This hospital-based cross-sectional observational study included 50 adult patients with clinical, biochemical, or imaging suspicion of portal hypertension. All patients underwent gray-scale ultrasonography and color Doppler evaluation. Liver echotexture, ascites, splenomegaly, portal vein diameter, portal vein diameter, splenic vein diameter, portal vein velocity, flow direction, hepatic vein waveform, and portosystemic collaterals were assessed. **Results:** Portal hypertension was detected in 45 patients (90%). The mean age was  $45.68 \pm 14.78$  years, and males constituted 68% of cases. Coarse liver echotexture and ascites were each seen in 76% of patients, while splenomegaly was present in 92%. Mean portal vein diameter was  $15.38 \pm 1.86$  mm, and mean portal vein velocity was  $11.50 \pm 3.38$  cm/s. Portosystemic collaterals were detected in 90% of patients. Ascites, splenomegaly, collaterals, and hepatic vein waveform were significantly associated with portal hypertension ( $p < 0.001$ ). Portal vein diameter increased and portal vein velocity decreased significantly with worsening Child–Pugh class. **Conclusion:** Ultrasonography with color Doppler is a useful non-invasive modality for evaluating portal hypertension. Portal vein velocity, hepatic vein waveform, portal vein diameter, and collateral detection are important parameters for diagnosis and severity assessment.

**Keywords:** Portal hypertension; ultrasonography; color Doppler; portal vein velocity; portal vein diameter; hepatic vein waveform; portosystemic collaterals.

## INTRODUCTION

Portal hypertension is a major hemodynamic consequence of chronic liver disease and represents a critical stage in the natural history of cirrhosis. It is defined by an abnormal elevation of the pressure gradient between the portal venous system and the systemic venous circulation. Hepatic venous pressure gradient measurement remains the reference standard for quantifying portal pressure, with portal hypertension generally defined when the gradient exceeds 5 mmHg and clinically significant portal hypertension recognized at values of 10 mmHg or higher.<sup>1,2</sup> Clinically significant portal hypertension is strongly associated with the development of decompensating events such as gastroesophageal varices, variceal hemorrhage, ascites, hepatic encephalopathy, and worsening hepatic failure.<sup>1,3</sup>

Cirrhosis remains the most common cause of portal hypertension worldwide. Progressive hepatic fibrosis, regenerative nodule formation, sinusoidal

capillarization, and intrahepatic endothelial dysfunction together increase resistance to portal venous inflow. This structural resistance is further amplified by dynamic vascular changes, including increased intrahepatic vasoconstriction and reduced nitric oxide bioavailability within the cirrhotic liver.<sup>2,3</sup> In parallel, splanchnic vasodilatation increases portal venous inflow, producing a hyperdynamic circulatory state that further sustains portal pressure. The combined effect of increased vascular resistance and increased splanchnic flow results in collateral vessel formation, splenomegaly, hypersplenism, ascites, and variceal development.<sup>3,4</sup>

The clinical importance of portal hypertension lies not only in its frequency but also in its prognostic implications. Variceal bleeding remains one of the most serious complications and is associated with substantial morbidity and mortality. Current clinical practice therefore emphasizes early recognition of portal hypertension, identification of high-risk patients, and timely institution of preventive or therapeutic interventions.<sup>4</sup> Although endoscopy is essential for direct

assessment of esophageal and gastric varices, imaging plays a central role in evaluating the portal venous system, detecting collateral pathways, assessing vascular patency, and identifying associated features of chronic liver disease.

Hepatic venous pressure gradient measurement is the most reliable method for direct hemodynamic assessment; however, it is invasive, technically demanding, costly, and not widely available in many routine clinical settings.<sup>2</sup> These limitations have led to increasing reliance on non-invasive modalities for the initial evaluation and follow-up of patients with suspected portal hypertension. Ultrasonography, particularly when combined with color and spectral Doppler, is widely used because it is safe, inexpensive, repeatable, and accessible. It provides simultaneous morphological and functional assessment of the liver, spleen, portal vein, splenic vein, hepatic veins, and portosystemic collateral circulation.<sup>5,6</sup>

Gray-scale ultrasonography can demonstrate several indirect features of chronic liver disease and portal hypertension, including altered liver echotexture, surface nodularity, caudate lobe prominence, splenomegaly, ascites, and dilatation of the portal and splenic veins. Color Doppler adds important hemodynamic information by allowing assessment of the direction, velocity, and pattern of blood flow within the portal venous system.<sup>6,7</sup> Normal portal venous flow is hepatopetal, continuous, and mildly phasic with respiration. In portal hypertension, Doppler may demonstrate reduced portal vein velocity, increased portal vein diameter, loss of respiratory variation, hepatofugal flow, portal vein thrombosis, cavernous transformation, and the presence of portosystemic collaterals.<sup>6,7</sup>

Several Doppler-derived parameters have been proposed for evaluation of portal hypertension. Portal vein diameter, portal vein flow velocity, splenic vein diameter, hepatic vein waveform pattern, and the presence of collaterals are among the most commonly assessed indices. The portal vein congestion index, introduced as the ratio of portal vein cross-sectional area to mean portal flow velocity, reflects venous stasis and has been studied as a marker of portal hemodynamic disturbance.<sup>8</sup> Similarly, alteration of hepatic vein waveform from the normal triphasic pattern to biphasic or monophasic forms may indicate reduced hepatic compliance in cirrhosis and has been associated with increasing severity of liver disease.<sup>6,7</sup>

Despite the usefulness of Doppler ultrasonography, its diagnostic performance depends on technical factors, operator expertise, patient habitus, bowel gas, equipment settings, and the criteria used for interpretation. A systematic review evaluating ultrasonography in cirrhotic portal hypertension reported variable accuracy across individual sonographic parameters, suggesting

that combined assessment of multiple gray-scale and Doppler features is more useful than reliance on a single measurement.<sup>9</sup> More recent reviews have similarly emphasized that ultrasound should be interpreted as a multiparametric tool, integrating liver morphology, spleen size, portal venous flow, hepatic venous waveform, collateral circulation, and associated complications.<sup>5,10</sup>

In resource-limited healthcare settings, including many parts of India, Doppler ultrasonography has particular practical value. It can be used as a first-line imaging modality for patients with suspected portal hypertension, for follow-up of known chronic liver disease, and for identifying patients who require further evaluation by endoscopy, cross-sectional imaging, or interventional procedures. However, Doppler findings may vary across patient populations and institutional settings, and local data remain important for defining the spectrum of sonographic findings and their clinical relevance.

The present study was therefore undertaken to evaluate the role of ultrasonography and color Doppler in portal hypertension. The study aimed to describe the spectrum of gray-scale and Doppler findings, assess flowmetric changes in the portal venous system, and identify the presence of portosystemic collaterals. By correlating morphological and hemodynamic parameters, the study seeks to strengthen the evidence for Doppler ultrasonography as a non-invasive, accessible, and clinically useful modality in the evaluation of portal hypertension.

## MATERIALS AND METHODS

**Study design and setting:** This was a hospital-based, cross-sectional observational study conducted in the Department of Radiodiagnosis, Mahatma Gandhi Medical College and Hospital, Jaipur. The study was carried out over a period of 18 months, from February 2024 to August 2025, after obtaining approval from the Institutional Ethics Committee.

**Study population:** The study population comprised adult patients referred to the Department of Radiodiagnosis with clinical, biochemical, or ultrasonographic suspicion of portal hypertension. Patients with suspected cirrhosis-related portal hypertension, known esophageal varices, or imaging findings suggestive of portal hypertension were considered eligible for inclusion. All eligible patients presenting during the study period and fulfilling the selection criteria were enrolled after obtaining written informed consent.

**Ethical considerations:** Prior approval was obtained from the Institutional Ethics Committee before initiation of the study. Written informed consent was obtained from all participants before enrollment. The purpose and procedure of the study were explained to each patient in

a language they could understand. Patient confidentiality was maintained throughout the study, and the collected data were used only for academic and research purposes.

**Sample size:** All patients fulfilling the inclusion criteria and presenting to the Department of Radiodiagnosis during the study period were included. Thus, the study followed a time-bound consecutive sampling method.

**Inclusion criteria & Exclusion criteria:** Adult patients referred with clinical and biochemical suspicion of cirrhosis with portal hypertension, adult patients with esophageal varices and portal hypertension, and patients willing to provide written informed consent were included in the study. Patients who did not provide consent, pediatric patients, and pregnant women were excluded from the study.

**Clinical and laboratory evaluation:** A detailed clinical history was recorded for all enrolled patients. Clinical details included history of hematemesis, melena, jaundice, weight loss, ascites, splenomegaly, alcoholism, and hepatitis B surface antigen status. Relevant biochemical parameters were also recorded, including serum total bilirubin, serum albumin, and prothrombin time/international normalized ratio. Disease severity was assessed using the Child–Pugh classification wherever sufficient clinical and biochemical data were available.

**Ultrasonography and color Doppler examination:** All patients underwent gray-scale ultrasonography followed by color and spectral Doppler examination for evaluation of portal hypertension and associated findings. Ultrasonography and Doppler examinations were performed using WIPRO GE LOGIQ P9 R3, WIPRO GE LOGIQ S8, SAMSUNG HS 50, and PHILIPS AFFINITY 30 ultrasound machines. Curvilinear and high-frequency linear probes were used as required according to patient habitus and the anatomical structure being evaluated. Gray-scale ultrasonography was performed to assess liver size, liver echotexture, surface irregularity, presence of ascites, spleen size, and splenomegaly. Color Doppler evaluation was then performed to assess the portal venous system, splenic vein, hepatic veins, and portosystemic collateral circulation.

**Doppler parameters assessed:** The following Doppler parameters were recorded: portal vein diameter, portal vein flow velocity, direction of portal venous flow, splenic vein diameter, hepatic vein waveform pattern, and presence of portosystemic collaterals. Portal venous flow direction was classified as hepatopetal, hepatofugal, or bidirectional. Hepatic vein waveform was classified as triphasic, biphasic, or monophasic. Portosystemic collaterals, when present, were documented according to their type, including splenorenal, paraumbilical, coronary, and gastrosplenic collaterals.

**Image analysis:** All ultrasonographic and Doppler findings were analyzed at the time of examination on the respective ultrasound machines. Measurements were

recorded in a structured proforma. Portal vein diameter and splenic vein diameter were measured in millimeters, while portal vein flow velocity was recorded in centimeters per second. Spleen size was recorded in centimeters. The presence or absence of ascites, splenomegaly, altered portal flow, hepatic vein waveform abnormality, and portosystemic collaterals was documented for each patient.


**Study variables:** The independent variables included demographic factors such as age and sex; etiological factors such as alcoholism, HBsAg status, and final diagnosis; clinical variables such as ascites, splenomegaly, and history of gastrointestinal bleeding; biochemical variables including serum bilirubin, serum albumin, and PT/INR; and disease severity according to Child–Pugh class.

The dependent variables included gray-scale and Doppler ultrasonographic findings such as liver echotexture, liver size, spleen size, portal vein diameter, portal vein flow velocity, direction of portal venous flow, splenic vein diameter, hepatic vein waveform pattern, presence of portosystemic collaterals, and type of collaterals.

The primary outcome variables were the spectrum of sonographic and Doppler findings in portal hypertension, flowmetric changes in the portal venous system, and the presence and type of portosystemic collaterals. Secondary outcome variables included the association of portal vein diameter and Doppler parameters with severity of liver disease, biochemical markers, and etiological factors.

**Operational definitions:** For the purpose of this study, portal hypertension was considered when ultrasonography and Doppler findings showed features such as increased portal vein diameter, altered portal venous flow dynamics, splenomegaly, ascites, or portosystemic collateral formation. Splenomegaly was defined as spleen size greater than normal limits on ultrasonography. Altered portal venous flow was defined as reduced portal flow velocity or change in direction of portal venous flow. Severity of liver disease was classified according to the Child–Pugh scoring system into Class A, Class B, and Class C.

**Statistical analysis:** Data were entered into a spreadsheet and analyzed using appropriate statistical methods. Quantitative variables were expressed as mean and standard deviation, while qualitative variables were expressed as frequency and percentage. Associations between categorical variables were assessed using the chi-square test or Fisher's exact test, as appropriate. Correlations between Doppler parameters and biochemical variables were assessed using suitable correlation tests according to the distribution of data. A p-value of less than 0.05 was considered statistically significant.



# Journal of Surgical Radiology

Site: <https://journalsurgrad.com/>

## RESULTS

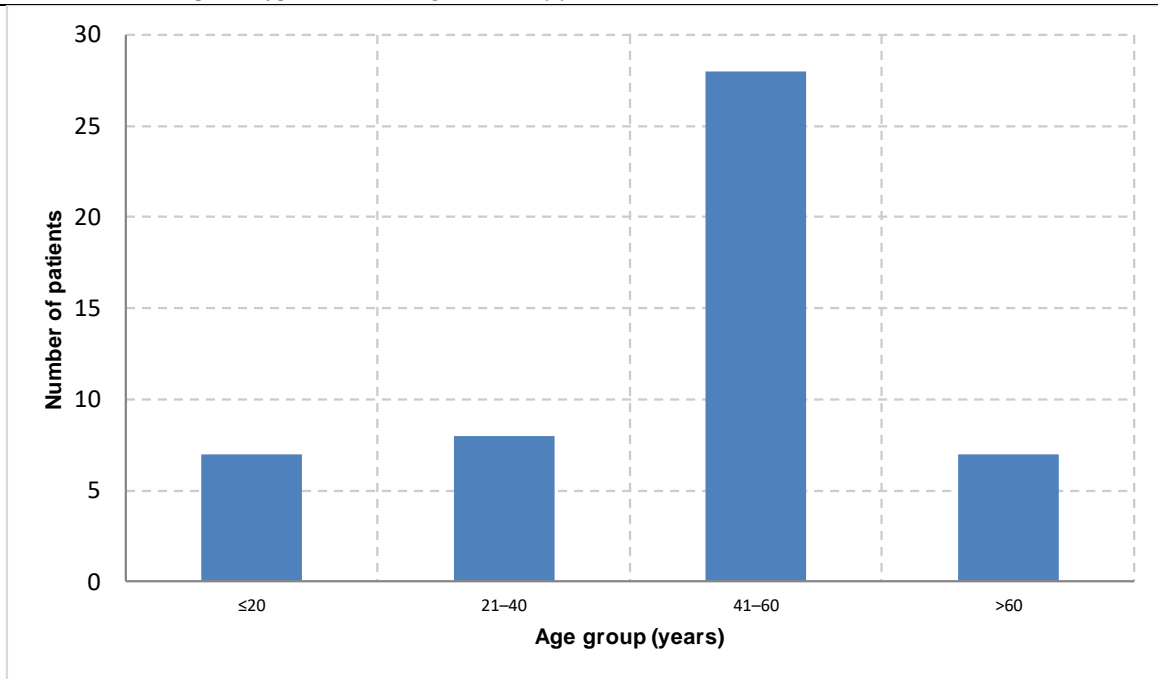
The present study included 50 patients who were evaluated for suspected or confirmed portal hypertension using gray-scale ultrasonography and color Doppler. The results were analyzed according to demographic profile, clinical presentation, ultrasonographic findings, Doppler parameters, final diagnosis, and association of imaging findings with portal hypertension and disease severity.

### Demographic and clinical profile

The mean age of the study population was  $45.68 \pm 14.78$  years. The majority of patients belonged to the 41–60 years age group, accounting for 28 cases (56.0%), followed by 21–40 years in 8 cases (16.0%). Patients aged  $\leq 20$  years and  $>60$  years constituted 7 cases (14.0%) each. There was a male predominance, with 34 males (68.0%) and 16 females (32.0%). A history of alcoholism was present in 18 patients (36.0%), while HBsAg positivity was observed in 7 patients (14.0%). Gastrointestinal bleeding was present in 24 patients (48.0%), indicating that nearly half of the study population had clinically significant manifestations of portal hypertension.

**Table 1. Demographic and clinical profile of study participants**

Variable	Category	Frequency	Percentage
Age group	$\leq 20$ years	7	14.0
	21–40 years	8	16.0
	41–60 years	28	56.0
	$>60$ years	7	14.0
Sex	Male	34	68.0
	Female	16	32.0
Alcoholism	Present	18	36.0
	Absent	32	64.0
HBsAg status	Positive	7	14.0
	Negative	43	86.0
Gastrointestinal bleeding	Present	24	48.0
	Absent	26	52.0



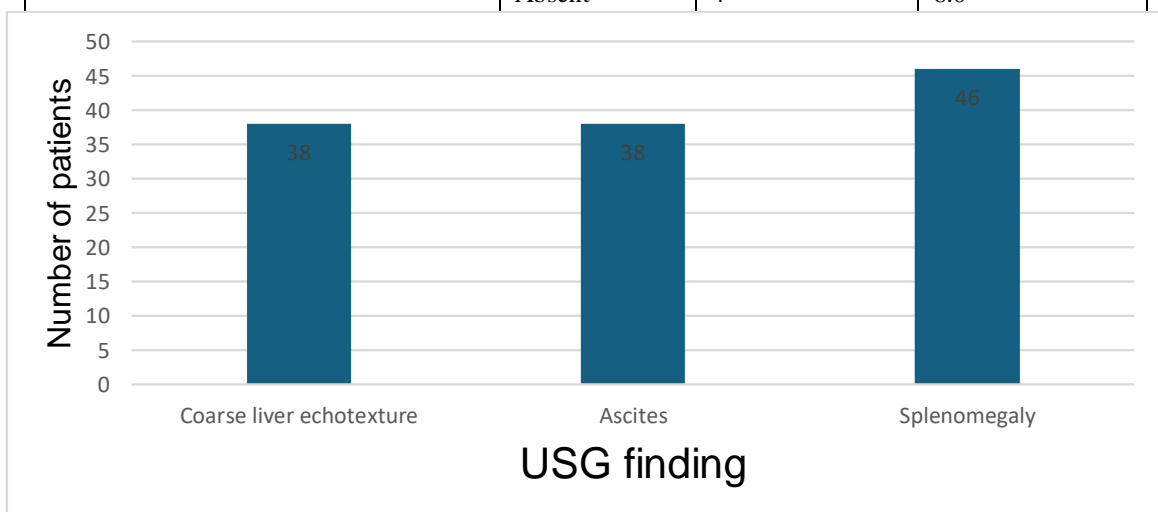
**Figure 1. Age and sex distribution of study participants.**

**Ultrasonographic findings**

On gray-scale ultrasonography, coarse liver echotexture was observed in 38 patients (76.0%), while 12 patients (24.0%) had normal liver echotexture. Ascites was present in 38 patients (76.0%), suggesting a high proportion of decompensated liver disease. Splenomegaly was observed in 46 patients (92.0%), making it one of the most common ultrasonographic findings in the study.

**Table 2. Gray-scale ultrasonographic findings**

Ultrasonographic finding	Category	Frequency	Percentage
Liver echotexture	Coarse	38	76.0
	Normal	12	24.0
Ascites	Present	38	76.0
	Absent	12	24.0
Splenomegaly	Present	46	92.0
	Absent	4	8.0



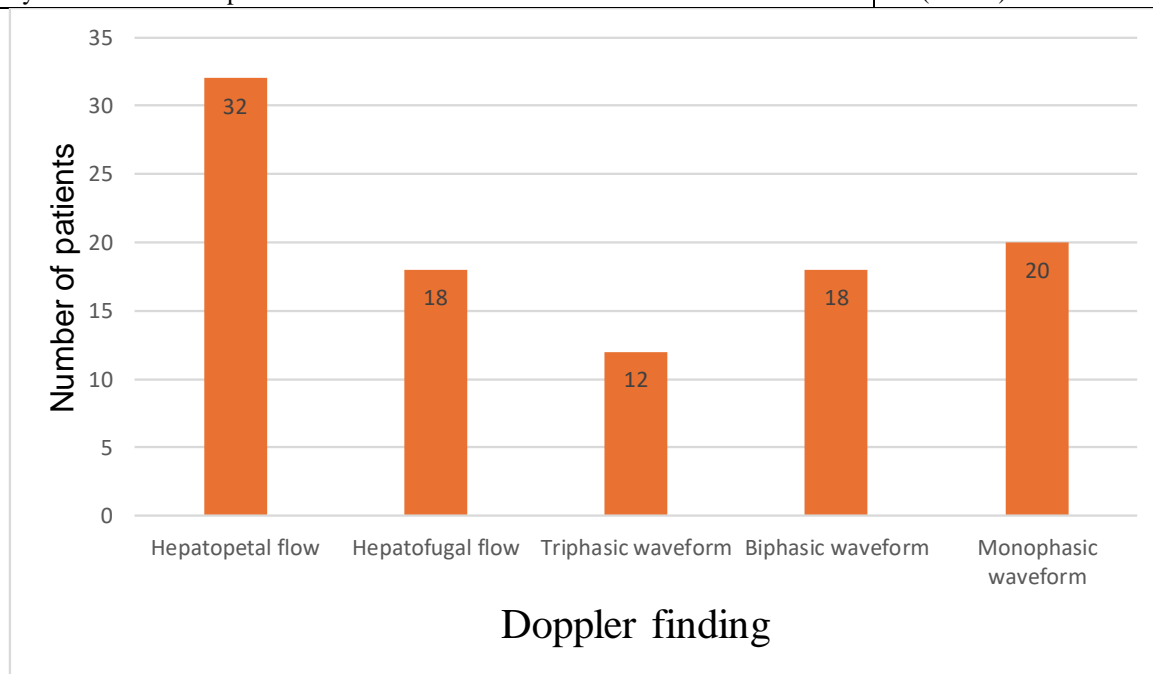
**Figure 2. Distribution of major ultrasonographic findings.**

**Doppler findings**

The mean portal vein diameter was  $15.38 \pm 1.86$  mm, indicating portal vein dilatation. The mean splenic vein diameter was  $11.70 \pm 1.28$  mm, while the mean portal vein velocity was reduced to  $11.50 \pm 3.38$  cm/s. Hepatopetal portal flow was observed in 32 patients (64.0%), whereas hepatofugal flow was present in 18 patients (36.0%). Hepatic vein waveform abnormality was common: monophasic waveform was seen in 20 patients (40.0%), biphasic waveform in 18 patients (36.0%), and normal triphasic waveform in only 12 patients (24.0%). Portosystemic collaterals were detected in 45 patients (90.0%), confirming chronic portal hypertension in most cases.

**Table 3. Doppler parameters and flow characteristics**

Doppler variable	Finding
Portal vein diameter, mm	$15.38 \pm 1.86$
Splenic vein diameter, mm	$11.70 \pm 1.28$
Portal vein velocity, cm/s	$11.50 \pm 3.38$
Hepatopetal portal flow	32 (64.0%)
Hepatofugal portal flow	18 (36.0%)
Triphasic hepatic vein waveform	12 (24.0%)
Biphasic hepatic vein waveform	18 (36.0%)
Monophasic hepatic vein waveform	20 (40.0%)
Portosystemic collaterals present	45 (90.0%)



**Figure 3. Portal vein flow direction and hepatic vein waveform pattern.**

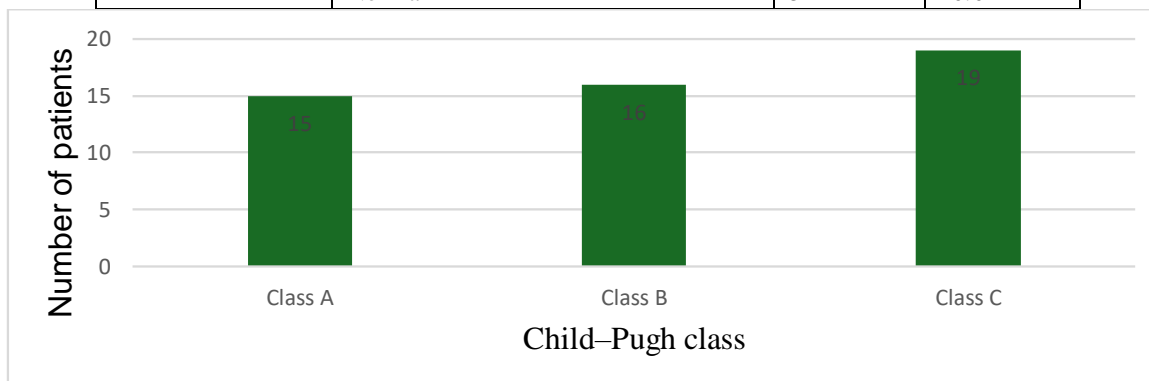
**Disease profile and final diagnosis**

Portal hypertension was present in 45 patients (90.0%), while 5 patients (10.0%) had no evidence of portal hypertension on imaging. According to Child–Pugh classification, 15 patients (30.0%) were in Class A, 16 patients (32.0%) were in Class B, and 19 patients (38.0%) were in Class C, indicating that advanced liver disease was common in the study population. Cirrhosis was the most frequent final diagnosis, seen in 26 patients (52.0%). Extrahepatic portal venous obstruction was observed in 7 patients (14.0%), portal vein thrombosis in 5 patients (10.0%), cirrhosis with hepatocellular carcinoma in 4 patients (8.0%), and Budd–Chiari syndrome in 3 patients (6.0%). Five patients (10.0%) had normal findings.

**Table 4. Disease severity and final diagnosis**

Variable	Category	Frequency	Percentage
Portal hypertension	Present	45	90.0
	Absent	5	10.0
Child–Pugh class	A	15	30.0
	B	16	32.0
	C	19	38.0
Final diagnosis	Cirrhosis	26	52.0
	Extrahepatic portal venous obstruction	7	14.0

	Portal vein thrombosis	5	10.0
	Cirrhosis with HCC	4	8.0
	Budd–Chiari syndrome	3	6.0
	Normal	5	10.0



**Figure 4. Distribution of Child–Pugh class and final diagnosis.**

Association of ultrasonographic and Doppler findings with portal hypertension: Ascites, splenomegaly, portosystemic collaterals, and hepatic vein waveform pattern showed statistically significant associations with portal hypertension. Ascites was present in all patients with portal hypertension and absent in all patients without portal hypertension, except for 7 patients with portal hypertension who did not have ascites. This association was statistically significant ( $p < 0.001$ ). Splenomegaly was present in 45 of 45 patients with portal hypertension and in only 1 patient without portal hypertension, showing a significant association ( $p < 0.001$ ). Portosystemic collaterals were seen exclusively in patients with portal hypertension and were significantly associated with portal hypertension ( $p < 0.001$ ). Hepatic vein waveform pattern also showed a significant association, as all patients with biphasic and monophasic waveforms had portal hypertension, while triphasic waveform was more commonly seen in patients without portal hypertension ( $\chi^2 = 17.59$ ,  $p < 0.001$ ). Portal vein flow direction did not show a statistically significant association with portal hypertension ( $p = 0.145$ ).

**Table 5. Association of ultrasonographic and Doppler findings with portal hypertension**

Variable	Category	PH present n (%)	PH absent n (%)	Test used	p-value
Ascites	Present	38 (100.0)	0 (0.0)	Fisher's exact test	<0.001
	Absent	7 (58.3)	5 (41.7)		
Splenomegaly	Present	45 (97.8)	1 (2.2)	Fisher's exact test	<0.001
	Absent	0 (0.0)	4 (100.0)		
Collaterals	Present	45 (100.0)	0 (0.0)	Fisher's exact test	<0.001
	Absent	0 (0.0)	5 (100.0)		
Portal vein flow direction	Hepatopetal	27 (84.4)	5 (15.6)	Fisher's exact test	0.145
	Hepatofugal	18 (100.0)	0 (0.0)		
Hepatic vein waveform	Triphasic	7 (58.3)	5 (41.7)	Chi-square test	<0.001
	Biphasic	18 (100.0)	0 (0.0)		
	Monophasic	20 (100.0)	0 (0.0)		

#### Association with disease severity

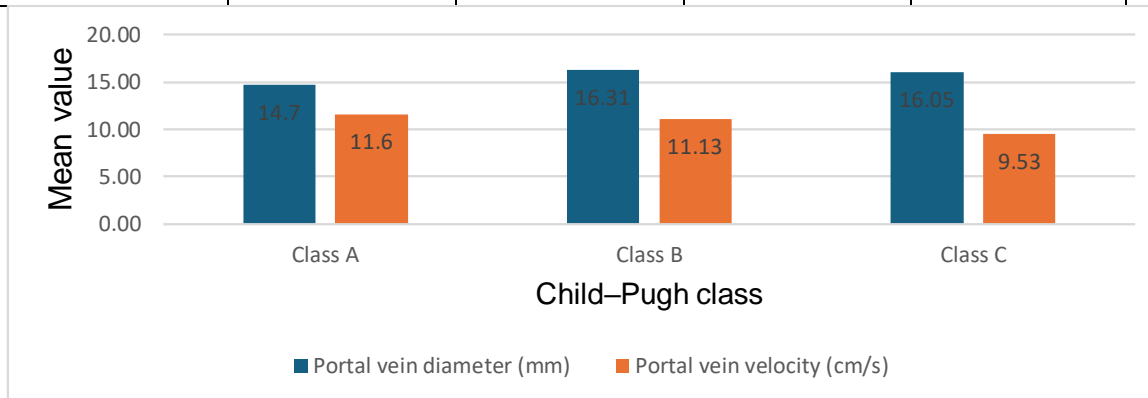
Alcoholism, HBsAg positivity, gastrointestinal bleeding, portal vein flow direction, and hepatic vein waveform pattern showed statistically significant associations with Child–Pugh class. Hepatic vein waveform pattern showed the strongest association with disease severity ( $\chi^2 = 66.80$ ,  $p < 0.001$ ), followed by portal vein flow direction ( $\chi^2 = 33.64$ ,  $p < 0.001$ ), alcoholism ( $\chi^2 = 27.13$ ,  $p < 0.001$ ), gastrointestinal bleeding ( $\chi^2 = 20.21$ ,  $p < 0.001$ ), and HBsAg status ( $\chi^2 = 9.60$ ,  $p = 0.008$ ).

On comparison of quantitative Doppler parameters across Child–Pugh classes, portal vein diameter showed a statistically significant difference among the groups ( $F = 6.72$ ,  $p = 0.003$ ). The mean portal vein diameter increased from  $14.70 \pm 0.82$  mm in Class A to  $16.31 \pm 1.25$  mm in Class B and  $16.05 \pm 1.18$  mm in Class C. Portal vein velocity showed a statistically significant decline with worsening Child–Pugh class ( $F = 6.86$ ,  $p = 0.003$ ), decreasing from  $11.60 \pm 1.17$  cm/s in Class A to  $11.13 \pm 0.89$  cm/s in Class B and  $9.53 \pm 2.20$  cm/s in Class C. Splenic vein diameter showed a mild increasing trend across Child–Pugh classes but was not statistically significant ( $p = 0.243$ ).

**Table 6. Doppler parameters according to Child–Pugh class**

Variable	Class A Mean $\pm$ SD	Class B Mean $\pm$ SD	Class C Mean $\pm$ SD	Test used	p-value
----------	-----------------------	-----------------------	-----------------------	-----------	---------

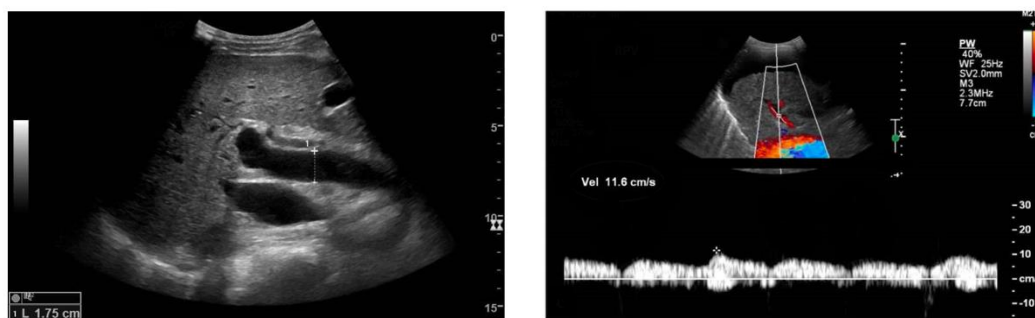
Portal vein diameter, mm	14.70 ± 0.82	16.31 ± 1.25	16.05 ± 1.18	One-way ANOVA	0.003
Portal vein velocity, cm/s	11.60 ± 1.17	11.13 ± 0.89	9.53 ± 2.20	One-way ANOVA	0.003
Splenic vein diameter, mm	11.80 ± 0.79	11.94 ± 0.77	12.26 ± 0.73	One-way ANOVA	0.243



**Figure 5. Comparison of portal vein diameter and portal vein velocity across Child-Pugh classes.**

#### Correlation of Doppler parameters with disease severity

Correlation analysis showed that portal vein diameter had a significant positive correlation with disease severity ( $r = +0.35$ ,  $p = 0.019$ ), indicating that portal vein diameter increased as Child-Pugh class worsened. Portal vein velocity showed a significant negative correlation with disease severity ( $r = -0.47$ ,  $p = 0.001$ ), indicating progressive reduction in portal venous velocity with increasing severity of liver disease. Splenic vein diameter showed a positive but statistically non-significant correlation with disease severity ( $r = +0.25$ ,  $p = 0.100$ ).



**Figure 6. Ultrasonography and color Doppler findings in portal hypertension.**

A: Dilated portal vein suggestive of portal hypertension. B: Spectral Doppler showing reduced portal vein velocity, indicating impaired portal venous flow and increased intrahepatic resistance.

Overall, the study demonstrated that ultrasonography and color Doppler are useful in the evaluation of portal hypertension. The most consistent findings were increased portal vein diameter, reduced portal vein velocity, splenomegaly, ascites, altered hepatic vein waveform, and presence of portosystemic collaterals. Among the Doppler parameters, portal vein velocity and hepatic vein waveform pattern showed strong association with disease severity, supporting the value of Doppler ultrasonography as a non-invasive method for assessing both the presence and severity of portal hypertension.

## DISCUSSION

Portal hypertension is an important complication of chronic liver disease and is closely associated with decompensation, variceal bleeding, ascites, splenomegaly, and collateral formation. Although hepatic venous pressure gradient remains the reference standard for assessment, it is invasive and not routinely available in many clinical settings.<sup>1,2</sup> Therefore, gray-scale ultrasonography with color Doppler has become an important non-invasive modality for evaluating both structural and hemodynamic changes in portal hypertension.<sup>5,6</sup> The present study evaluated 50 patients

with suspected or confirmed portal hypertension and demonstrated that Doppler ultrasonography provides useful information regarding portal vein diameter, portal vein velocity, hepatic vein waveform, splenomegaly, ascites, and portosystemic collateral circulation.

In the present study, the majority of patients belonged to the 41–60 years age group, with a mean age of  $45.68 \pm 14.78$  years. This suggests that portal hypertension predominantly affected middle-aged individuals, which is expected because chronic liver disease usually progresses over several years before significant portal hypertension develops. A male predominance was

observed, with males constituting 68% of the study population. This may be related to higher exposure to risk factors such as alcohol consumption. A history of alcoholism was present in 36% of patients, and HBsAg positivity was seen in 14%, indicating that both alcohol-related liver disease and chronic viral hepatitis contributed to the disease profile. Gastrointestinal bleeding was present in 48% of patients, suggesting that a substantial proportion had already developed clinically significant or advanced portal hypertension. Variceal bleeding is one of the most serious consequences of portal hypertension and is strongly associated with clinically significant portal pressure.<sup>1,4</sup>

Gray-scale ultrasonography showed coarse liver echotexture in 76% of patients, ascites in 76%, and splenomegaly in 92%. These findings are consistent with chronic liver disease and raised portal venous pressure. Splenomegaly was the most frequent sonographic finding in the present study, supporting its role as an important indirect marker of portal hypertension. However, splenomegaly alone may not reliably indicate severity, as it can be influenced by chronicity of disease, collateral decompression, and hypersplenism. Shi et al. also highlighted the relationship between portal hemodynamics and hypersplenism in cirrhosis, supporting the clinical relevance of spleen-related changes in portal hypertension.<sup>20</sup>

The mean portal vein diameter in this study was  $15.38 \pm 1.86$  mm, which was above the commonly accepted upper normal limit of approximately 13 mm.<sup>5,6</sup> Portal vein diameter increased significantly with worsening Child–Pugh class, indicating that portal vein dilatation reflects increasing portal venous congestion and disease progression. Similar observations were reported by Mittal et al., who found that portal vein Doppler findings were associated with disease severity in cirrhotic patients with portal hypertension.<sup>11</sup> Shateri et al. also reported that sonographic portal vein diameter and flow velocity have clinical relevance in cirrhotic patients.<sup>16</sup> Thus, portal vein diameter is a useful structural marker, although it should be interpreted along with functional Doppler findings.

Portal vein velocity was an important functional parameter in the present study. The mean portal vein velocity was  $11.50 \pm 3.38$  cm/s, which is lower than normal portal venous flow.<sup>6,15</sup> Portal vein velocity decreased significantly with worsening Child–Pugh class, and correlation analysis showed a significant negative correlation with disease severity ( $r = -0.47$ ,  $p = 0.001$ ). This indicates that increasing hepatic dysfunction and intrahepatic resistance are associated with progressive reduction in portal venous flow. Afif et al. reported that Doppler parameters of the hepatic vein, portal vein, and hepatic artery correlate with Child–Pugh score in cirrhosis.<sup>13</sup> Iranpour et al. also described reduced portal venous velocity and altered flow patterns as important Doppler abnormalities in cirrhotic patients.<sup>15</sup>

Therefore, portal vein velocity appears to be one of the most sensitive Doppler indicators of disease severity.

The mean splenic vein diameter was  $11.70 \pm 1.28$  mm, indicating splenic venous dilatation. However, it did not show a statistically significant association with Child–Pugh class. This suggests that splenic vein diameter reflects portal venous congestion but may be less reliable as a severity marker when used alone. In contrast, portal vein flow direction showed greater clinical relevance. Hepatopetal flow was observed in 64% of patients, while hepatofugal flow was present in 36%. Although flow direction was not significantly associated with the presence of portal hypertension, it showed significant association with Child–Pugh class. Hepatofugal flow is generally considered a late sign of portal hypertension and reflects advanced hemodynamic disturbance. von Herbay et al. demonstrated the usefulness of color Doppler in identifying spontaneous portosystemic shunts and abnormal portal flow direction in cirrhotic patients.<sup>19</sup>

Hepatic vein waveform was one of the strongest Doppler markers in the present study. Normal triphasic waveform was seen in only 24% of patients, while biphasic and monophasic waveforms were observed in 36% and 40%, respectively. Hepatic vein waveform showed a highly significant association with both portal hypertension and Child–Pugh class. The change from triphasic to biphasic or monophasic waveform reflects reduced hepatic compliance due to fibrosis, nodularity, and increased intrahepatic resistance. McNaughton and Abu-Yousef emphasized the importance of hepatic venous Doppler waveform interpretation in liver disease.<sup>6</sup> Sudhamshu et al. also re-evaluated hepatic vein waveforms in cirrhosis and reported their relationship with cirrhotic hemodynamics.<sup>12</sup> Ohta et al. further demonstrated the prognostic significance of flat hepatic vein waveform in cirrhotic patients with portal hypertension.<sup>18</sup> These findings support the present observation that hepatic vein waveform is a useful marker of advanced disease.

Portosystemic collaterals were detected in 90% of patients, and their presence was significantly associated with portal hypertension. Collateral formation is a hallmark of chronic portal hypertension and represents compensatory decompression of the portal venous system. The high prevalence of collaterals in this study suggests that many patients presented at an advanced or chronic stage. Color Doppler is particularly useful in detecting collateral pathways and spontaneous portosystemic shunts.<sup>19</sup> In the present study, the combination of collateral detection, reduced portal velocity, increased portal vein diameter, and altered hepatic vein waveform provided strong non-invasive evidence of portal hypertension.

Child–Pugh classification showed that 38% of patients were in Class C, followed by Class B in 32% and Class A in 30%, indicating that advanced liver disease was common in the study population. Portal vein diameter

increased significantly with worsening Child–Pugh class, while portal vein velocity decreased significantly. The correlation analysis further showed a positive correlation between portal vein diameter and severity and a negative correlation between portal vein velocity and severity. These findings support the concept that portal hypertension should be assessed using a multiparametric Doppler approach rather than relying on a single measurement. Kim et al., in a systematic review, also reported that the accuracy of ultrasonography varies across individual parameters and that combined assessment improves diagnostic utility.<sup>9</sup>

Overall, the present study demonstrates that ultrasonography with color Doppler is a valuable, non-invasive, repeatable, and clinically useful modality for evaluating portal hypertension. Among the studied parameters, portal vein velocity and hepatic vein waveform showed the strongest relationship with disease severity, while portal vein diameter, splenomegaly, ascites, and collaterals provided important supportive information. The findings are particularly relevant in routine clinical and resource-limited settings where invasive HVPG measurement may not be feasible.

The study has certain limitations. It was a single-centre study with a relatively small sample size, which may limit generalisability. HVPG measurement was not performed, so direct comparison with the gold standard could not be made. Doppler ultrasonography is operator-dependent and may be affected by patient habitus, bowel gas, and technical factors. In addition, the cross-sectional design did not allow assessment of disease progression or treatment response. Despite these limitations, the study supports the routine use of multiparametric Doppler ultrasonography for diagnosis and severity assessment of portal hypertension.

Overall, the present findings reinforce that Doppler ultrasonography is not only useful for detecting portal hypertension but also for assessing its severity. A combined evaluation of portal vein diameter, portal vein velocity, hepatic vein waveform, splenomegaly, ascites, and collaterals provides a comprehensive non-invasive assessment and can help guide further clinical management.

## CONCLUSION

The present study concludes that ultrasonography combined with color Doppler is a reliable, non-invasive, cost-effective, and readily available modality for the evaluation of portal hypertension. It provides comprehensive information about both structural and hemodynamic changes, including portal vein dilatation, reduced portal vein velocity, altered hepatic vein waveform, ascites, splenomegaly, and portosystemic collaterals. Among the evaluated parameters, portal vein velocity and hepatic vein waveform showed the strongest association with disease severity, while portal vein diameter and collateral formation were important

supportive diagnostic markers. Therefore, multiparametric Doppler ultrasonography can be considered a useful first-line imaging tool for diagnosis, severity assessment, and follow-up of patients with suspected portal hypertension, particularly in routine clinical and resource-limited settings.

## Recommendation

Ultrasonography with color Doppler should be routinely used in patients with suspected or confirmed chronic liver disease for early detection and assessment of portal hypertension. A combined Doppler approach including portal vein diameter, portal vein velocity, hepatic vein waveform, flow direction, splenic vein diameter, ascites, splenomegaly, and portosystemic collaterals should be followed to improve diagnostic accuracy. Patients with reduced portal vein velocity, hepatofugal flow, monophasic hepatic vein waveform, or collaterals should undergo closer clinical follow-up and appropriate evaluation for complications such as esophageal varices. Larger multicentric studies with longitudinal follow-up are recommended to validate these findings and to determine whether Doppler parameters can predict clinical outcomes and disease progression.

## REFERENCES

1. de Franchis R, Bosch J, Garcia-Tsao G, Reiberger T, Ripoll C, Baveno VII Faculty. Baveno VII—Renewing consensus in portal hypertension. *J Hepatol*. 2022;76(4):959-974.
2. Bosch J, Abraldes JG, Berzigotti A, Garcia-Pagan JC. The clinical use of HVPG measurements in chronic liver disease. *Nat Rev Gastroenterol Hepatol*. 2009;6(10):573-582.
3. D’Amico G, Garcia-Tsao G, Pagliaro L. Natural history and prognostic indicators of survival in cirrhosis: a systematic review of 118 studies. *J Hepatol*. 2006;44(1):217-231.
4. Garcia-Tsao G, Abraldes JG, Berzigotti A, Bosch J. Portal hypertensive bleeding in cirrhosis: risk stratification, diagnosis, and management—2016 practice guidance by the American Association for the Study of Liver Diseases. *Hepatology*. 2017;65(1):310-335.
5. Maruyama H, Yokosuka O. Ultrasonography for noninvasive assessment of portal hypertension. *Gut Liver*. 2017;11(4):464-473.
6. McNaughton DA, Abu-Yousef MM. Doppler US of the liver made simple. *Radiographics*. 2011;31(1):161-188.
7. Han SK, Kim MY, Kang SH. Application of ultrasound for the diagnosis of cirrhosis/portal hypertension. *Clin Mol Hepatol*. 2022;28(2):206-222.
8. Moriyasu F, Nishida O, Ban N, Nakamura T, Sakai M, Miyake T, et al. “Congestion index” of the portal vein. *AJR Am J Roentgenol*. 1986;146(4):735-739.
9. Kim G, Cho YZ, Baik SK. The accuracy of ultrasonography for the evaluation of portal hypertension in patients with cirrhosis: a systematic review. *Korean J Radiol*. 2015;16(2):314-324.

10. Berzigotti A. Assessing portal hypertension in liver diseases. *Expert Rev Gastroenterol Hepatol*. 2013;7(2):141-155.
11. Mittal P, Gupta R, Mittal G, Kalia V. Association between portal vein color Doppler findings and the severity of disease in cirrhotic patients with portal hypertension. *Iran J Radiol*. 2011;8(4):211-217.
12. Sudhamshu KC, Sharma D, Chataut SP. Hepatic vein waveforms in liver cirrhosis re-evaluated. *Hepatol Int*. 2011;5(1):581-585.
13. Afif AM, Chamarthy MR, Lin E, Kumar N. A sonographic Doppler study of the hepatic vein, portal vein and hepatic artery in liver cirrhosis: correlation of hepatic hemodynamics with clinical Child–Pugh score in Singapore. *Ultrasound*. 2017;25(4):213-221.
14. Antil N, Sureka B, Mittal MK, Malik A, Gupta B, Thukral BB. Hepatic venous waveform, splenoportal and damping index in liver cirrhosis: correlation with Child Pugh’s score and oesophageal varices. *J Clin Diagn Res*. 2016;10(2):TC01-TC05.
15. Iranpour P, Lall C, Houshyar R, Helmy M, Yang A, Choi JI, et al. Altered Doppler flow patterns in cirrhosis patients: an overview. *Ultrasonography*. 2016;35(1):3-12.
16. Shateri K, Mohammadi A, Moloudi F, Nosair E, Ghasemi-Rad M. Correlation between sonographic portal vein diameter and flow velocity with the clinical scoring systems MELD and CTP in cirrhotic patients: is there a relationship? *Gastroenterol Res Pract*. 2012;2012:685935.
17. Katwal S, Maharjan S, Shrestha S, Sharma P, Shrestha S. Measurement of portal vein indices and splenic index by ultrasonography and Doppler in patients with liver cirrhosis. *J Nepal Health Res Counc*. 2023;21(2):231-236.
18. Ohta M, Hashizume M, Tomikawa M, Ueno K, Tanoue K, Sugimachi K. Prognostic significance of hepatic vein waveform by Doppler ultrasonography in cirrhotic patients with portal hypertension. *Am J Gastroenterol*. 1995;90(10):1853-1857.
19. von Herbay A, Frieling T, Häussinger D. Color Doppler sonographic evaluation of spontaneous portosystemic shunts and inversion of portal venous flow in patients with cirrhosis. *J Clin Ultrasound*. 2000;28(7):332-339.
20. Shi BM, Wang XY, Mu QL, Wu TH, Xu J. Value of portal hemodynamics and hypersplenism in cirrhosis staging. *World J Gastroenterol*. 2005;11(5):708-711.
- 21.