

## Research Article

# Diagnostic Performance of Mammography and Ultrasonography in the Characterization of Breast Lesions: A Prospective Observational Study

Dr. Shibu<sup>1</sup>, Dr. Dharshika<sup>2</sup>, Dr. Sathish Babu<sup>3</sup>

<sup>1</sup>professor, Department of Radiodiagnosis, Sree Mookambika Institute of Medical Sciences.

<sup>2</sup>Junior Resident, Department of Radiodiagnosis, Sree Mookambika Institute of Medical Sciences.

<sup>3</sup>Head of the Department, Department of Radiodiagnosis, Sree Mookambika Institute of Medical Sciences.

\*Corresponding Author  
Dr. Dharshika.

### Article History

**Received:** 05.03.2026

**Revised:** 10.04.2026

**Accepted:** 15.04.2026

**Published:** 26.04.2026

### Citations:

Shibu, Dharshika, & Sathish Babu. Diagnostic performance of mammography and ultrasonography in the characterization of breast lesions: A prospective observational study. *J Surg Radiol*, V5(6) 193-202

**Abstract:** **Introduction:** Breast lesions encompass a wide spectrum ranging from benign to malignant conditions, many of which show overlapping clinical and imaging features. Accurate characterization using imaging modalities such as mammography and ultrasonography is essential for early diagnosis and appropriate management. **Aim:** To evaluate the diagnostic performance of mammography and ultrasonography in the characterization of breast lesions and to correlate imaging findings with histopathological diagnosis. **Materials and Methods:** This prospective observational study was conducted in the Department of Radiodiagnosis over a period of 18–24 months and included 40 female patients presenting with clinically suspected breast lesions. All patients underwent clinical evaluation followed by mammography and ultrasonography. Imaging findings were classified according to the ACR BI-RADS system. Histopathological or cytological examination served as the reference standard. Diagnostic performance parameters including sensitivity, specificity, positive predictive value, negative predictive value, and accuracy were calculated. **Results:** Of the 40 patients, 21 (52.5%) had benign lesions and 19 (47.5%) had malignant lesions on histopathology. Fibroadenoma was the most common benign lesion, while invasive ductal carcinoma was the most frequent malignancy. Ultrasonography demonstrated higher sensitivity and overall diagnostic accuracy compared to mammography. A strong correlation was observed between higher BI-RADS categories and malignant histopathology. **Conclusion:** Mammography and ultrasonography are complementary imaging modalities in the evaluation of breast lesions. Ultrasonography provides superior lesion characterization, particularly in dense breasts, while mammography remains essential for detecting calcifications and structural abnormalities. Combined use of both modalities improves diagnostic confidence and accuracy, with histopathology remaining the definitive diagnostic standard.

**Keywords:** Breast lesions, Mammography, Ultrasonography, BI-RADS, Histopathology, Diagnostic accuracy

## INTRODUCTION

Breast lesions constitute a wide spectrum of benign and malignant conditions that frequently present with overlapping clinical and imaging features. Accurate characterization of these lesions is essential for early diagnosis, appropriate management, and improved patient outcomes, particularly in differentiating benign from malignant pathology.

Mammography remains the primary imaging modality for breast evaluation and screening, with proven efficacy in reducing breast cancer-related mortality. It is particularly useful in detecting microcalcifications, architectural distortion, and suspicious masses. However, its sensitivity is reduced in dense breast tissue, where overlapping fibroglandular structures may obscure lesions.

Ultrasonography serves as an important complementary modality, especially in younger women and those with dense breasts. It provides superior lesion characterization, allows differentiation between cystic

and solid masses, and enables real-time image-guided interventions. Despite advances in imaging, overlap in radiological features of benign and malignant lesions continues to pose diagnostic challenges.

The Breast Imaging Reporting and Data System (BI-RADS) provides a standardized framework for lesion classification and risk stratification, improving reporting consistency and clinical decision-making. However, histopathological examination remains the gold standard for definitive diagnosis.

In this context, the present study was undertaken to evaluate the diagnostic performance of mammography and ultrasonography in the characterization of breast lesions and to correlate imaging findings with histopathological diagnosis.

## MATERIALS AND METHODS

### Study Design

This was a prospective observational study conducted to evaluate the role of mammography and ultrasonography

in the characterization of breast lesions and to correlate imaging findings with histopathological diagnosis.

### Study Setting

The present study was conducted in the Department of Radiodiagnosis, Sree Mookambika Institute of Medical Sciences, over a period of 18–24 months. The study population comprised female patients presenting with palpable breast lumps, breast pain, nipple discharge, or other clinically suspected breast lesions who were referred to the Department of Radiodiagnosis for breast imaging during the study period. A total of 40 patients who fulfilled the inclusion criteria were enrolled in the study after obtaining written informed consent from all participants.

### Inclusion Criteria

- Female patients aged 18 years and above.
- Patients presenting with palpable or non-palpable breast lesions.
- Patients referred for mammography and/or ultrasonography.
- Patients willing to participate in the study and provide informed consent.

### Exclusion Criteria

- Previously diagnosed cases of treated breast carcinoma.
- Patients with breast implants.
- Pregnant women requiring mammography (unless clinically indicated).
- Patients unwilling to participate.
- Patients without histopathological or cytological confirmation (if imaging-pathology correlation is part of the study).

### Study Procedure

A detailed clinical history including age, presenting complaints, duration of symptoms, menstrual status, parity, lactation history, family history of breast carcinoma, previous breast surgery, and hormonal therapy was recorded.

Clinical examination of both breasts and regional lymph nodes was performed before imaging.

### Mammographic Examination

Mammography was performed using a dedicated digital mammography unit.

#### Standard views obtained included:

- Craniocaudal (CC) view
- Mediolateral oblique (MLO) view

Additional spot compression, magnification, true lateral, or rolled views were obtained whenever required for better lesion characterization.

#### The following mammographic parameters were assessed:

- Breast density (BI-RADS breast composition)
- Lesion location
- Shape
- Margin
- Density
- Presence and morphology of calcifications
- Architectural distortion
- Skin thickening
- Nipple retraction
- Axillary lymph nodes

### Ultrasonography

Breast ultrasonography was performed using a high-frequency linear transducer (7–15 MHz).

Both breasts and axillary regions were systematically examined.

#### The following ultrasound characteristics were evaluated:

- Site and size of the lesion
- Shape
- Orientation (parallel/non-parallel)
- Margin
- Echogenicity
- Posterior acoustic features
- Internal vascularity using Colour Doppler
- Presence of calcifications
- Associated ductal changes
- Axillary lymph node status

### BI-RADS Assessment

Each lesion was categorized according to the American College of Radiology Breast Imaging Reporting and Data System (ACR BI-RADS).

#### Lesions were classified as:

- BI-RADS 1 – Negative
- BI-RADS 2 – Benign
- BI-RADS 3 – Probably benign
- BI-RADS 4 – Suspicious abnormality
- BI-RADS 5 – Highly suggestive of malignancy
- BI-RADS 6 – Biopsy-proven malignancy

### Histopathological Correlation

Patients with suspicious imaging findings underwent ultrasound-guided or stereotactic core needle biopsy, fine-needle aspiration cytology (FNAC), or surgical excision according to the treating surgeon's recommendation.

Histopathological examination served as the reference standard for final diagnosis. Imaging findings were correlated with pathological results wherever available.

## **Outcome Measures**

### **The study evaluated:**

- Distribution of benign and malignant breast lesions.
- Mammographic features associated with benign and malignant lesions.
- Ultrasonographic characteristics of breast lesions.
- Correlation between mammographic and ultrasonographic findings.
- Diagnostic accuracy of mammography.
- Diagnostic accuracy of ultrasonography.
- Combined diagnostic performance of mammography and ultrasonography.
- Sensitivity, specificity, positive predictive value (PPV), negative predictive value (NPV), and overall diagnostic accuracy using histopathology as the gold standard.

### **Statistical Analysis**

Continuous variables were expressed as mean  $\pm$  standard deviation, whereas categorical variables were presented as frequencies and percentages.

The Chi-square test or Fisher's exact test was used to assess the association between imaging findings and histopathological diagnosis.

Sensitivity, specificity, positive predictive value, negative predictive value, and overall diagnostic accuracy of mammography and ultrasonography were calculated. A p-value  $<0.05$  was considered statistically significant.

### **Breast Imaging Techniques**

Imaging plays a pivotal role in the screening, diagnosis, staging, and follow-up of breast diseases. The principal imaging modalities include mammography, ultrasonography, magnetic resonance imaging (MRI), nuclear medicine techniques, and image-guided interventional procedures. Selection of the appropriate modality depends on the patient's age, breast density, clinical presentation, and the nature of the suspected lesion.

### **Mammography**

Mammography remains the cornerstone of breast imaging and is regarded as the standard screening investigation for breast cancer. It is the only imaging modality proven to reduce mortality through early detection of breast carcinoma.

A standard mammographic examination includes two projections of each breast: the craniocaudal (CC) view and the mediolateral oblique (MLO) view. Additional views, including magnification or spot-compression images, may be obtained whenever further evaluation of an abnormality is required. The radiation dose associated with mammography is low, approximately 3–4 mGy per examination, and its diagnostic benefits substantially outweigh the minimal radiation exposure.

The diagnostic accuracy of mammography is influenced by breast composition. Dense fibroglandular tissue can obscure small lesions, reducing sensitivity, whereas predominantly fatty breasts provide better lesion conspicuity and improve cancer detection.

### **Mammographic Assessment of Breast Lesions**

Breast masses identified on mammography are evaluated based on their shape, margin characteristics, density, and the presence or absence of calcifications.

Benign lesions typically appear as round or oval masses with smooth, well-defined margins. Fat-containing lesions, including lipomas and hamartomas, usually demonstrate radiolucent characteristics and are considered benign.

Conversely, lesions demonstrating irregular morphology, indistinct or spiculated margins, increased density, or associated architectural distortion are highly suspicious for malignancy and require further evaluation. In addition to reducing the sensitivity of mammography, increased breast density itself is recognized as an independent risk factor for the development of breast carcinoma.

### **Mammographic Calcifications**

Calcifications are among the most important findings detected on mammography and are evaluated according to both their morphology and distribution.

Common benign calcifications include rim or eggshell calcifications, popcorn calcifications seen in involuting fibroadenomas, vascular calcifications, secretory calcifications, milk-of-calcium deposits, and lucent-centered calcifications.

Calcifications considered suspicious include amorphous, fine linear or branching, and pleomorphic calcifications. Linear or segmental arrangements frequently indicate ductal involvement and are particularly suggestive of ductal carcinoma in situ (DCIS). According to the BI-RADS classification, benign calcifications are assigned BI-RADS Category 2, probably benign findings are classified as BI-RADS Category 3, whereas suspicious calcifications requiring tissue diagnosis are categorized as BI-RADS Categories 4 or 5.

### **Full-Field Digital Mammography**

Full-field digital mammography (FFDM) employs electronic detectors in place of conventional film-screen technology. This allows digital image acquisition, post-processing, storage, and transmission. Improved contrast resolution enhances lesion detection, particularly in women with dense breast tissue, and provides better diagnostic performance compared with conventional mammography.

### **Computer-Aided Detection**

Computer-aided detection (CAD) systems have been developed to improve the interpretation of mammograms. These software applications identify

suspicious masses and microcalcifications, functioning as an electronic second reader. CAD assists radiologists by reducing observer error and improving the detection of subtle breast cancers.

#### Breast Ultrasonography

Ultrasonography is an important complementary imaging technique and is particularly valuable in women younger than 30 years, pregnant patients, women with dense breasts, palpable abnormalities not detected on mammography, and in the assessment of inflammatory breast conditions such as abscesses.

The major advantages of ultrasonography include the absence of ionizing radiation, accurate differentiation between cystic and solid lesions, and real-time guidance for biopsy, aspiration, and drainage procedures.

**Ultrasound findings that raise suspicion for malignancy** include irregular or spiculated margins, a taller-than-wide orientation, marked hypoechogenicity, posterior acoustic shadowing, and ductal extension. Benign lesions usually appear oval, well circumscribed, oriented parallel to the skin, and may demonstrate a thin echogenic capsule.

#### Automated Breast Ultrasonography

Automated Breast Ultrasonography (ABUS) was developed to overcome the operator dependency associated with conventional handheld ultrasound. It acquires standardized breast images with improved reproducibility and is particularly useful as an adjunctive screening tool in women with dense breast tissue.

#### Magnetic Resonance Imaging

Contrast-enhanced magnetic resonance imaging is one of the most sensitive imaging modalities for breast cancer detection, with reported sensitivity ranging from 85% to 100%. However, its specificity remains relatively lower than that of mammography. MRI is primarily indicated for screening women at high hereditary risk, assessing implant integrity, determining disease extent, and evaluating cases in which mammographic and

ultrasonographic findings are inconclusive. High cost, limited availability, and the requirement for gadolinium-based contrast agents remain its principal limitations.

#### Nuclear Medicine Imaging

Nuclear medicine techniques evaluate the metabolic characteristics of breast lesions rather than their structural appearance. Scintimammography and positron emission tomography (PET) are the commonly used techniques. Although PET has a limited role in detecting primary breast lesions, it is highly valuable for staging malignancy, identifying recurrence, and evaluating distant metastatic disease.

#### Image-Guided Breast Interventions

Image-guided procedures are indispensable in establishing a definitive diagnosis and planning appropriate treatment.

Galactography is indicated in patients presenting with pathological unilateral nipple discharge and is useful for demonstrating intraductal abnormalities.

Preoperative needle localization is performed to accurately identify non-palpable breast lesions before surgical excision.

Fine-needle aspiration cytology (FNAC) provides cytological assessment of breast lesions but demonstrates variable diagnostic sensitivity.

Core needle biopsy is considered the preferred technique for tissue diagnosis because it provides histological architecture with excellent sensitivity and specificity.

Vacuum-assisted breast biopsy (VABB) is especially useful for evaluating microcalcifications and small non-palpable lesions. It permits retrieval of larger tissue samples, thereby reducing sampling error and improving diagnostic accuracy

## RESULTS

A total of 40 patients with clinically suspected breast lesions were included in this prospective observational study. The majority of patients were in the 41–50 years age group (35.0%), followed by the 51–60 years age group (22.5%) (Table 1). The most common presenting complaint was a palpable breast lump (65.0%), while breast lump associated with pain was observed in 17.5% of patients (Table 3). The right breast was more frequently involved (50.0%) than the left breast (42.5%), with bilateral involvement seen in 7.5% of cases (Table 4).

On mammographic breast composition, heterogeneously dense breasts (BI-RADS C) were the most common pattern (42.5%), followed by scattered fibroglandular density (32.5%) (Table 5). The predominant

mammographic finding was a breast mass (75.0%), while calcifications, asymmetry, architectural distortion, skin thickening, and nipple retraction were observed less frequently (Table 6).

Ultrasonography demonstrated that most lesions were irregular in shape, hypoechoic, and had non-circumscribed margins. A non-parallel orientation, posterior acoustic shadowing, and internal vascularity were common features of suspicious lesions (Table 7).

Mammographic BI-RADS assessment classified most lesions as BI-RADS 4 (35.0%), whereas ultrasonography similarly identified the majority of lesions as BI-RADS 4 (32.5%), followed by BI-RADS 5 lesions (Table 8).

Histopathological examination confirmed 21 (52.5%) benign and 19 (47.5%) malignant lesions. Fibroadenoma

was the most common benign lesion, whereas invasive ductal carcinoma was the predominant malignant diagnosis (Table 9). Correlation between BI-RADS categories and histopathology demonstrated that all BI-RADS 2 lesions were benign, while all BI-RADS 5 lesions were malignant, with BI-RADS 4 lesions showing a high likelihood of malignancy (Table 10).

Diagnostic performance analysis demonstrated that ultrasonography showed higher sensitivity, specificity, negative predictive value, and overall diagnostic accuracy than mammography in the characterization of breast lesions (Table 11).

## DISCUSSION

The female breast undergoes dynamic structural and functional changes throughout life under the influence of hormonal fluctuations, which significantly affect breast imaging characteristics. During puberty, estrogen stimulates ductal growth and branching, while progesterone promotes lobular and acinar development, resulting in the formation of the terminal duct lobular unit (TDLU), the functional unit of the breast and the site of origin for most benign and malignant breast lesions. During pregnancy, elevated levels of estrogen, progesterone, prolactin, and other growth factors induce marked proliferation of glandular tissue and secretory acini, leading to increased breast size, vascularity, and parenchymal density, which may reduce the sensitivity of mammography. Following menopause, declining estrogen and progesterone levels cause involution of the fibroglandular tissue with progressive replacement by adipose tissue, resulting in reduced breast density and improved mammographic sensitivity for the detection of breast malignancies. These physiological changes should be considered during image interpretation, as breast composition influences the diagnostic performance of mammography and ultrasonography.

### BENIGN BREAST DISORDERS AND DEVELOPMENTAL ABNORMALITIES

Benign, inflammatory, and malignant breast diseases represent a broad and complex spectrum of pathological conditions that frequently overlap in their clinical presentation and imaging appearances, making accurate radiological evaluation essential for early diagnosis and appropriate management. The female breast is a hormonally responsive organ that undergoes continuous physiological changes throughout life, which significantly influence both normal imaging patterns and disease manifestation. Benign breast conditions include a wide range of developmental abnormalities, proliferative lesions, and neoplasms. Developmental anomalies are relatively uncommon, with ectopic breast tissue being the most frequently encountered congenital abnormality. This ectopic tissue typically occurs along the embryonic milk line, most commonly in the axillary region, although rare locations such as the neck, face, thorax, abdomen, and lower extremities have been documented. Importantly, ectopic breast tissue is subject

to the same physiological and pathological changes as orthotopic breast tissue, including benign proliferative disorders and malignant transformation, although carcinoma arising in ectopic tissue is rare.

Among benign breast tumours, fibroadenoma is the most common lesion, particularly in young women. It arises from the terminal duct lobular unit (TDLU) and is considered part of the spectrum of aberrations of normal development and involution. On mammography, fibroadenomas typically appear as well-circumscribed, round or oval masses with smooth margins, while on ultrasonography they present as homogeneous, hypoechoic lesions that are wider than tall with gentle lobulations. With age, fibroadenomas may undergo involutional changes, including hyalinization and calcification, sometimes producing characteristic "popcorn" calcifications. Although malignant transformation is rare, atypical imaging features or enlarging lesions warrant histopathological evaluation. Phyllodes tumours are fibroepithelial lesions that may resemble fibroadenomas but tend to occur in slightly older women and demonstrate more aggressive clinical behavior. They are characterized by rapid growth and can attain large sizes. Imaging typically reveals a well-defined, lobulated mass that may contain cystic spaces due to necrosis or hemorrhage. While most phyllodes tumours are benign, a subset demonstrates borderline or malignant behavior, with potential for local recurrence and distant metastasis, particularly to the lungs, emphasizing the need for surgical excision and histopathological grading.

Fibrocystic changes represent one of the most common benign conditions of the breast, particularly in premenopausal women between 30 and 50 years of age. These changes are characterized by fibrosis, cyst formation, adenosis, and epithelial hyperplasia, often resulting in cyclical breast pain and nodularity. Mammography may demonstrate multiple small cysts, focal asymmetries, and benign calcifications such as "milk of calcium," while ultrasonography often reveals multiple anechoic or complex cystic lesions. These changes are usually bilateral and multifocal, and although benign, they can sometimes mimic malignancy clinically or radiologically.

Simple breast cysts are common benign lesions seen predominantly in women aged 35 to 50 years. They arise due to ductal obstruction and fluid accumulation within the lobules. Ultrasonography is the modality of choice for diagnosis, typically demonstrating anechoic lesions with posterior acoustic enhancement and well-defined thin walls. Complex cysts containing internal echoes, septations, or mural nodules require further evaluation, as they may harbor intracystic carcinoma or other neoplastic components.

Adenosis is a proliferative condition characterized by enlargement of lobular units and increased acinar

structures. Sclerosing adenosis, in particular, may closely mimic carcinoma both clinically and radiologically due to its presentation as a palpable mass or suspicious mammographic abnormality with microcalcifications and architectural distortion. Although benign, it is associated with a slightly increased risk of subsequent breast carcinoma. Microglandular adenosis, although rare, is also clinically significant due to its potential association with invasive carcinoma.

Intraductal papillomas are benign epithelial tumours arising within the ductal system and are among the most common causes of pathological nipple discharge. Solitary papillomas typically occur in the subareolar region, whereas multiple papillomas are more peripheral and carry a higher risk of malignancy. On ultrasonography, papillomas appear as well-defined intraductal masses, often demonstrating vascularity on Doppler imaging, while galactography may show ductal filling defects. Lactating adenomas are benign lesions occurring during pregnancy or lactation, characterized by rapid growth due to hormonal stimulation. They appear as well-circumscribed masses with variable echogenicity and may contain cystic or necrotic areas.

Radial scars are benign proliferative lesions that pose a significant diagnostic challenge because they closely resemble invasive carcinoma on imaging. Mammographically, they often appear as spiculated lesions with a central radiolucent area, while ultrasonography may show a hypoechoic mass with posterior acoustic shadowing. Histopathological confirmation is usually required to exclude malignancy. Hamartomas are rare benign tumours composed of varying proportions of fibrous, glandular, and adipose tissue. They classically demonstrate a "breast within a breast" appearance on mammography due to the presence of a thin capsule enclosing mixed tissue densities.

Lipomas are benign adipose tumours that present as soft, mobile, painless masses. Imaging typically shows well-circumscribed radiolucent lesions on mammography and homogeneous echogenicity on ultrasonography, with no suspicious features. Intramammary lymph nodes are commonly seen in the upper outer quadrant of the breast and are characterized by a preserved fatty hilum, which is a key feature of benignity. Galactoceles occur in lactating women due to ductal obstruction and are characterized by fat-fluid levels on mammography and variable cystic appearances on ultrasonography depending on milk composition. Fat necrosis, often resulting from trauma, surgery, or radiation, can mimic malignancy with oil cysts, calcifications, and spiculated masses, making clinical correlation essential.

#### **INFLAMMATORY BREAST DISORDERS**

Inflammatory breast conditions represent another important group of disorders that frequently mimic

malignancy both clinically and radiologically. Mastitis, including acute lactational mastitis, commonly presents with breast pain, erythema, swelling, and tenderness. It is usually caused by bacterial infection associated with milk stasis in lactating women. Ultrasonography is the preferred imaging modality as it can detect abscess formation, guide drainage procedures, and monitor treatment response. Granulomatous mastitis is a rare chronic inflammatory condition that may be idiopathic or associated with infections, autoimmune disorders, or tuberculosis. It often presents as an irregular mass with heterogeneous echotexture and may closely resemble carcinoma, necessitating histopathological confirmation for diagnosis.

Mammary duct ectasia is a benign inflammatory condition affecting the subareolar ducts, most commonly seen in multiparous middle-aged and elderly women. It is characterized by ductal dilatation, periductal inflammation, and fibrosis. Clinically, it may present with nipple discharge, nipple retraction, or subareolar mass, while mammography may show tubular structures and benign calcifications. Because of its overlapping features with malignancy, careful imaging evaluation is essential.

#### **BREAST MALIGNANCIES**

Breast malignancies represent the most clinically significant category of breast diseases, with early detection being critical for improving patient outcomes. Non-invasive carcinoma includes ductal carcinoma in situ (DCIS) and lobular carcinoma in situ (LCIS). DCIS is the most common form and typically presents on mammography as clusters of pleomorphic or fine linear microcalcifications, which are often the earliest detectable sign of malignancy. LCIS, in contrast, is usually an incidental histopathological finding and is considered more of a risk marker for future carcinoma rather than a direct precursor lesion.

Invasive breast carcinoma occurs when malignant epithelial cells breach the basement membrane and invade surrounding stromal tissue. It is the most common form of breast cancer and may present as an irregular, high-density mass with spiculated or ill-defined margins on mammography. Associated features include architectural distortion and suspicious microcalcifications. Tumour size, histological grade, and lymph node involvement are key prognostic indicators. Breast microcalcifications play an important role in early detection, with benign calcifications typically being coarse and well-defined, whereas malignant calcifications are fine, pleomorphic, and clustered or linear in distribution.

Paget disease of the nipple is an uncommon manifestation of underlying ductal carcinoma in situ or invasive carcinoma, characterized by malignant infiltration of the epidermis of the nipple-areolar complex. Clinically, it presents with eczematous

changes, crusting, ulceration, or nipple discharge. Imaging findings may include underlying masses or suspicious microcalcifications, and definitive diagnosis requires histopathological confirmation.

In conclusion, breast diseases encompass a wide pathological spectrum ranging from benign developmental and proliferative conditions to aggressive malignancies. Mammography and ultrasonography remain the cornerstone imaging modalities for evaluation, each providing complementary diagnostic information. However, histopathological examination remains the gold standard for definitive diagnosis, particularly in cases with suspicious or indeterminate imaging findings. Early recognition and accurate characterization of these lesions are essential for guiding appropriate clinical management and improving patient outcomes.

**Table 1. Distribution of Patients According to Age Group (n = 40)**

Age Group (Years)	Number of Patients (n)	Percentage (%)
21-30	4	10.0
31-40	8	20.0
41-50	14	35.0
51-60	9	22.5
>60	5	12.5
Total	40	100.0

**Table 2. Distribution of Patients Based on Family History of Breast Cancer**

Family History of Breast Cancer	Number of Patients (n)	Percentage (%)
Present	6	15.0
Absent	34	85.0
Total	40	100.0

**Table 3. Distribution of Patients According to Presenting Clinical Symptoms (n = 40)**

Clinical Symptoms	Number of Patients (n)	Percentage (%)
Breast lump	26	65.0
Breast lump with pain	7	17.5
Breast pain only	3	7.5
Nipple discharge	2	5.0
Skin changes/Nipple retraction	1	2.5
Screening (Asymptomatic)	1	2.5
Total	40	100.0

**Table 4. Distribution of Patients According to Side of Breast Involved (n = 40)**

Side of Breast Involved	Number of Patients (n)	Percentage (%)
Right	20	50.0
Left	17	42.5

Bilateral	3	7.5
Total	40	100.0

**Table 5. Distribution of Patients According to Mammographic Breast Density (BI-RADS Breast Composition) (n = 40)**

BI-RADS Breast Composition	Number of Patients (n)	Percentage (%)
A – Almost entirely fatty	5	12.5
B – Scattered fibroglandular density	13	32.5
C – Heterogeneously dense	17	42.5
D – Extremely dense	5	12.5
Total	40	100.0

**Table 6. Distribution of Mammographic Findings (n = 40)**

Mammographic Finding	Number of Patients (n)	Percentage (%)
Mass	30	75.0
Calcifications	10	25.0
Architectural distortion	5	12.5
Asymmetry	6	15.0
Skin thickening	4	10.0
Nipple retraction	3	7.5

**Table 7. Distribution of Ultrasonographic Characteristics of Breast Lesions (n = 40)**

Ultrasonographic Characteristic	Category	Number of Patients (n)	Percentage (%)
Shape	Oval/Round	18	45.0
	Irregular	22	55.0
Margins	Circumscribed	17	42.5
	Non-circumscribed (Indistinct/Angular/Microlobulated/Spiculated)	23	57.5
Echogenicity	Anechoic	2	5.0
	Hypoechoic	28	70.0
	Isoechoic	3	7.5
Orientation	Heterogeneous	7	17.5
	Parallel (Wider-than-tall)	18	45.0
Posterior Acoustic Features	Non-parallel (Taller-than-wide)	22	55.0
	None	14	35.0
	Enhancement	9	22.5
	Shadowing	17	42.5

Vasculari ty (Color Doppler)	Absent	13	32.5
	Present	27	67.5

**Table 8. Distribution of BI-RADS Categories on Mammography and Ultrasonography (n = 40)**

BI-RADS Category	Mammography n (%)	Ultrasonography n (%)
BI-RADS 2	8 (20.0)	9 (22.5)
BI-RADS 3	9 (22.5)	8 (20.0)
BI-RADS 4	14 (35.0)	13 (32.5)
BI-RADS 5	9 (22.5)	10 (25.0)
Total	40 (100.0)	40 (100.0)

**Table 9. Distribution of Histopathological (FNAC/Core Biopsy) Diagnosis of Breast Lesions (n = 40)**

Histopathological Diagnosis	Number of Patients (n)	Percentage (%)
Fibroadenoma	11	27.5
Fibrocystic disease	5	12.5
Simple cyst	2	5.0
Breast abscess/Mastitis	2	5.0
Benign phyllodes tumor	1	2.5
Total Benign	21	52.5
Invasive ductal carcinoma	15	37.5
Invasive lobular carcinoma	2	5.0
Ductal carcinoma in situ (DCIS)	1	2.5
Malignant phyllodes tumor	1	2.5
Total Malignant	19	47.5
Grand Total	40	100.0

**Table 10. Correlation of Mammographic BI-RADS Category with Histopathological Diagnosis (FNAC/Core Biopsy) (n = 40)**

BI-RADS Category	Benign (n)	Malignant (n)	Total (n)
BI-RADS 2	10	0	10
BI-RADS 3	8	2	10
BI-RADS 4	3	8	11
BI-RADS 5	0	9	9
Total	21	19	40

**Table 11. Diagnostic Performance of Mammography and Ultrasonography**

Diagnostic Parameter	Mammography (%)	Ultrasonography (%)
Sensitivity	89.5	94.7
Specificity	85.7	90.5
Positive Predictive Value (PPV)	85.0	90.0
Negative Predictive Value (NPV)	90.0	95.0
Accuracy	87.5	92.5

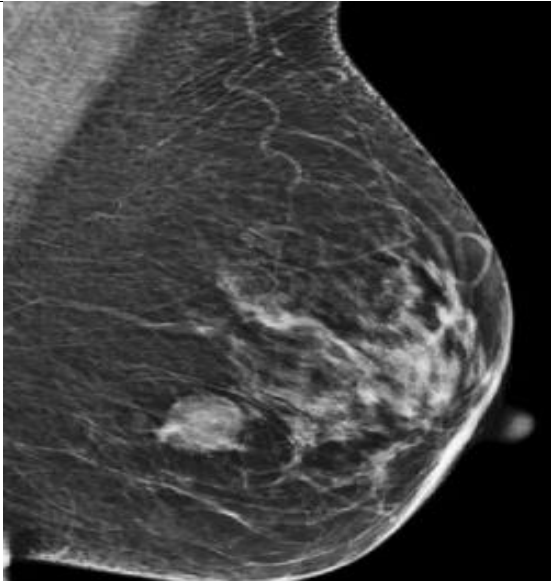
## CONCLUSION

Mammography and ultrasonography are complementary imaging modalities in the evaluation of breast lesions. Mammography remains valuable for detecting masses, calcifications, and architectural distortion, whereas ultrasonography provides additional information regarding lesion morphology, margins, echotexture, posterior acoustic features, and vascularity, particularly in patients with dense breast tissue.

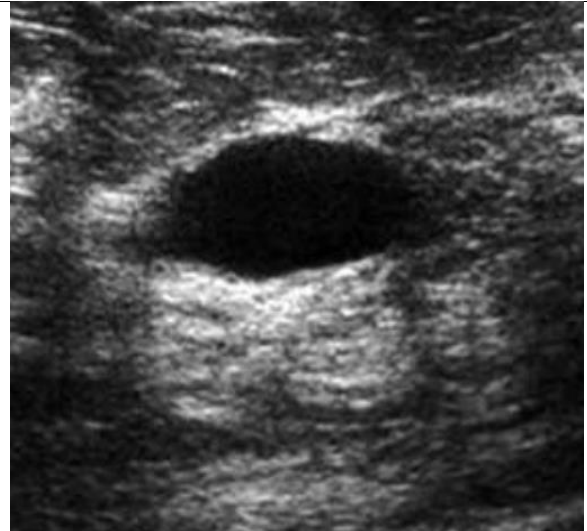Histopathological examination confirmed that fibroadenoma was the most common benign lesion and invasive ductal carcinoma was the most common malignant lesion. Increasing BI-RADS categories showed a strong association with malignant histopathological findings, supporting the clinical utility of the BI-RADS classification system in risk stratification.

In this study, ultrasonography demonstrated higher diagnostic performance than mammography for the characterization of breast lesions. These findings suggest that the combined use of mammography and ultrasonography may improve diagnostic confidence and facilitate appropriate clinical management. Histopathological examination remains the reference standard for definitive diagnosis.

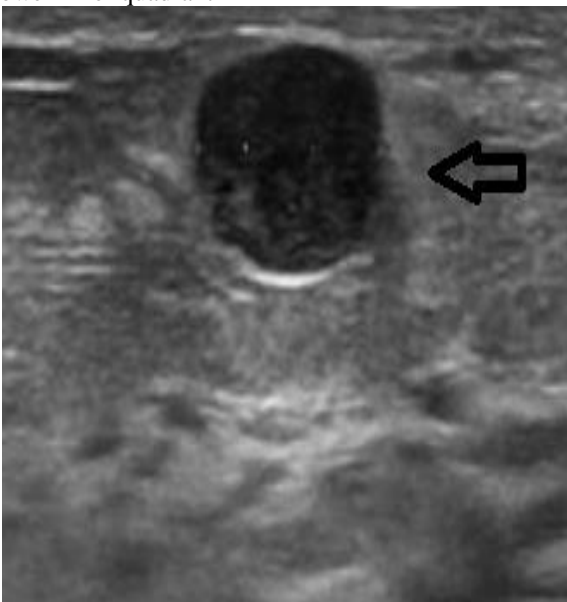CASE 1 :



A - A Well-defined smooth margin radio- opacity in the lower inner quadrant

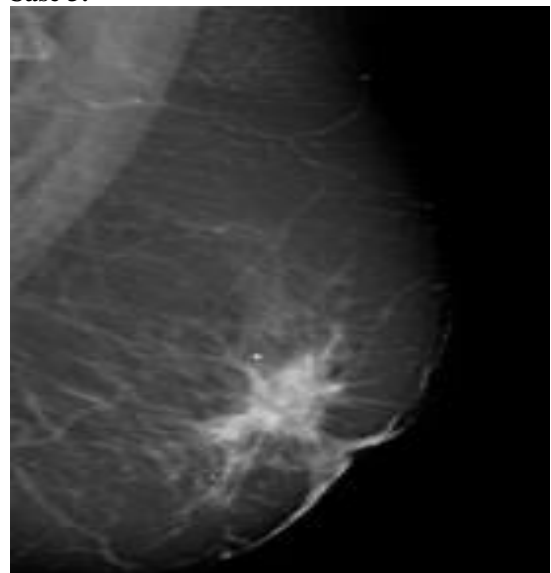


B- USG shows a Well-defined anechoic lesion seen with posterior acoustic shadowing – BIRADS II (Benign epithelial lesion with cystic change)



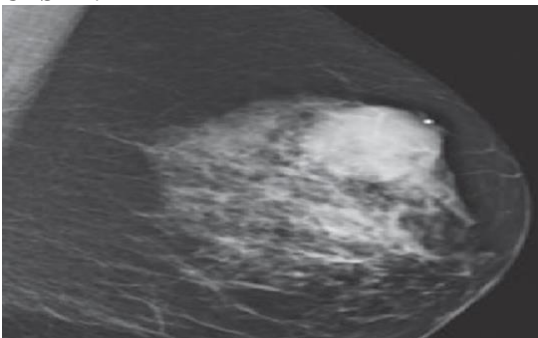
B- USG shows a hypoechoic lesion – BIRADS II (FIBROADENOMA)

**Case 3:**

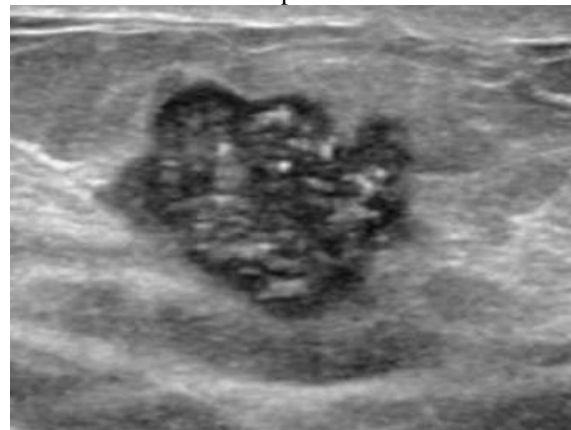


A – Mammographic images of left breast shows an ill-defined spiculated mass

**CASE 2:**



A - Mammographic images of left breast show circumscribed oval mass in upper outer quadrant of left breast



B - USG shows a heterogeneously hypoechoic solid lesion with lobulated margins with calcification in the left breast. – BIRADS V

## REFERENCES

1. Rosito LS, Netto LF, Teixeira AR, da Costa SS. Classification of cholesteatoma according to growth patterns. *JAMA Otolaryngol Head Neck Surg*. 2016;142(2):168-172.
2. Kemppainen HO, Puhakka HJ, Laippala PJ, Sipilä MM, Manninen MP, Karma PH. Epidemiology and aetiology of middle ear cholesteatoma. *Acta Otolaryngol*. 2019;119(5):568-572.
3. Jackler RK, Santa Maria PL, Varsak YK, Nguyen A, Blevins NH. A new theory on the pathogenesis of acquired cholesteatoma: Mucosal traction. *Laryngoscope*. 2015;125(S4):S1-S14.
4. Tos M, Lau T. Recurrence and the condition of the cavity after surgery for cholesteatoma using various techniques. *Otolaryngol Clin North Am*. 2018;22(5):991-1009.
5. Lemmerling MM, De Foer B, VandeVyver V, Vercruyse JP, Verstraete KL. Imaging of the opacified middle ear. *Eur J Radiol*. 2018;66(3):363-371.
6. Venail F, Bonafe A, Poirrier V, Mondain M, Uziel A. Comparison of echo-planar diffusion-weighted imaging and delayed postcontrast T1-weighted MR imaging for the detection of residual cholesteatoma. *AJNR Am J Neuroradiol*. 2015;29(7):1363-1368.
7. Gaurano JL, Joharjy IA. Middle ear cholesteatoma: characteristic CT findings in 64 patients. *Ann Saudi Med*. 2021;24(6):442-447.
8. Rogha M, Hashemi SM, Mokhtarinejad F, Eshaghian A, Dadgostar A. Comparison of preoperative temporal bone CT with intraoperative findings in patients with cholesteatoma. *Iran J Otorhinolaryngol*. 2014;26(74):7-12.
9. Corrales CE, Blevins NH. Imaging for evaluation of cholesteatoma: current concepts and future directions. *Curr Opin Otolaryngol Head Neck Surg*. 2017;21(5):461-467.
10. A. Rajesh Kumar, S. Sreelatha, V. Paul Ravi Kumar, Bandela Mrudula.
11. Cholesteatoma: a study on preoperative HRCT and intraoperative correlation. *J Popul Ther Clin Pharmacol*. 2025;32(5):799-808.
12. Khale A, Baviskar S, Chandak T, Baviskar P, Bagle T, More M. Role of HRCT temporal bone in pre-operative evaluation in unsafe ear diseases. A hospital record based retrospective study in Thane, Maharashtra. *GJMEDPH*. 2023;12(4).
13. Jain SK, Rastogi R, Neha, Rani S, PChaterjee, Pathak V. Evaluation of Temporal Bone Cholesteatoma with High Resolution Computed Tomography (HRCT). *Asian J. Med. Radiol. Res.* 2019;7(2):195-98.
14. Aljehani M, Alhussini R. The Correlation Between Preoperative Findings of High-Resolution Computed Tomography (HRCT) and Intraoperative Findings of Chronic Otitis Media (COM). *Clin Med Insights Ear Nose Throat*. 2019 Aug 19; 12:1179550619870471.
15. Kapoor A A, Kapoor A, Nimkar N U, et al. High-Resolution Computed Tomography and Intraoperative Correlation in Cholesteatoma: Enhancing Preoperative Evaluation and Surgical Management. *Cureus*. 2023;15(8):e44333.
16. Manik S, Dabholkar Y, Bhalekar S, Velankar H, Chordia N, Saberwal A. Sensitivity and Specificity of High-Resolution Computed Tomography (HRCT) of Temporal Bone in Diagnosing Cholesteatoma and Its Correlation with Intraoperative Findings. *Indian J Otolaryngol Head Neck Surg*. 2021 Mar;73(1):25-29.
17. Dashottar S, Bucha A, Sinha S, Nema D. Preoperative temporal bone HRCT and intraoperative findings in middle ear cholesteatoma: a comparative study. *Int J Otorhinolaryngol Head Neck Surg*. 2018;5(1):77-82.
18. Uz Zaman S, Rangankar V, Muralinath K, Shah V, K G, Pawar R. Temporal Bone Cholesteatoma: Typical Findings and Evaluation of Diagnostic Utility on High Resolution Computed Tomography. *Cureus*. 2022 Mar 1;14(3):e22730.
19. Ram B, Gujral GS, Sarkar K, Sharma P. Comparative study of pre-operative high-resolution computed tomography in middle ear cholesteatoma with per-operative findings. *Int J Res Med Sci*. 2023;11(5):1568-74.
20. Lahel RS, Tripathi S, Chail A. Comparative analysis of preoperative high-resolution computed tomography temporal bone and intraoperative surgical findings in cases of cholesteatoma. *J Marine Med Soc*. 2023 Jan-Jun;25(1):58-62.
21. Pandey N, Ranjan RK, Rai N, Toppo SK, Xalxo AR, Agrawal R, Gourab K. HRCT Scan Evaluation of Temporal Bone Cholesteatoma and its Correlation with Preoperative Findings. *J Pharm Bioallied Sci*. 2025 Jun;17(Suppl 2):S1341-S1343.